

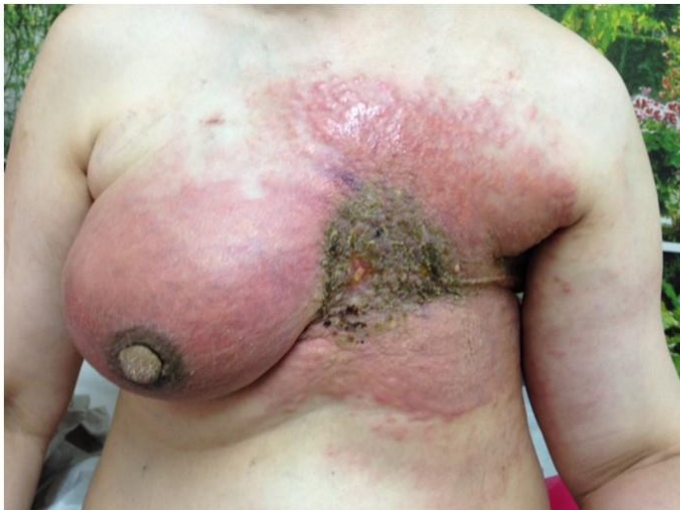Advanced cancer cases treated by combination of EHY-2000 and EHY-3010

Dr. Joseph Brenner

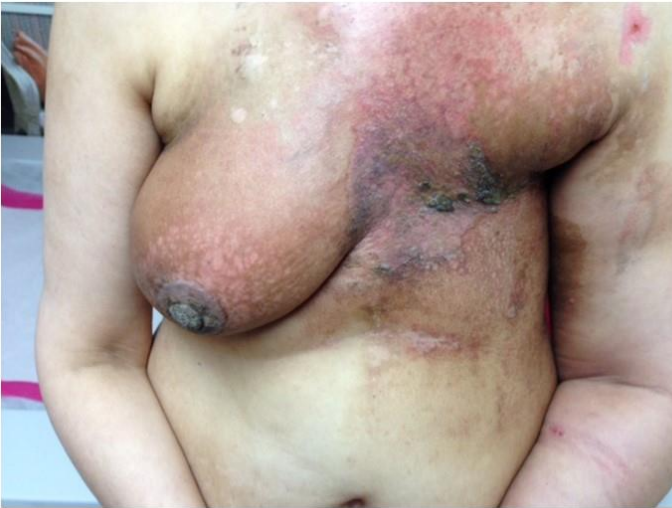Cite this article as:

<http://oncotherm.com/sites/oncotherm/files/2017-10/Pages%20from%20Oncothermia%20Journal%20volume%2020-6.pdf>

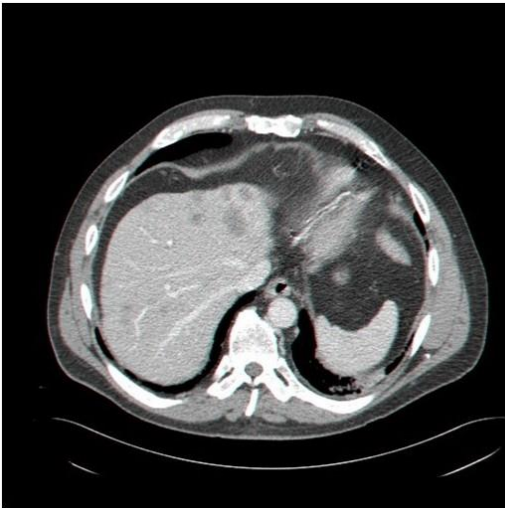Dr. Joseph Brenner
ESHO 2017. 21- 23 June, Athens



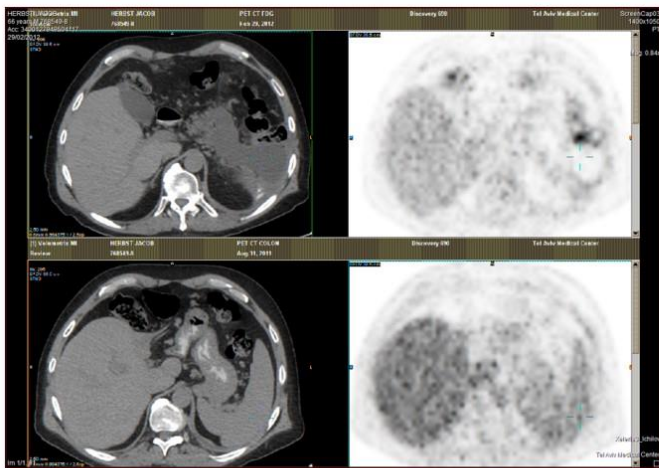
Local recurrence of breast cancer to the whole chest wall: treatment with EHY-3000 to the whole chest, with EHY-2000 to the massive recurrent mass in the left chest wall and treatment with superficial hyperthermia to the skin.



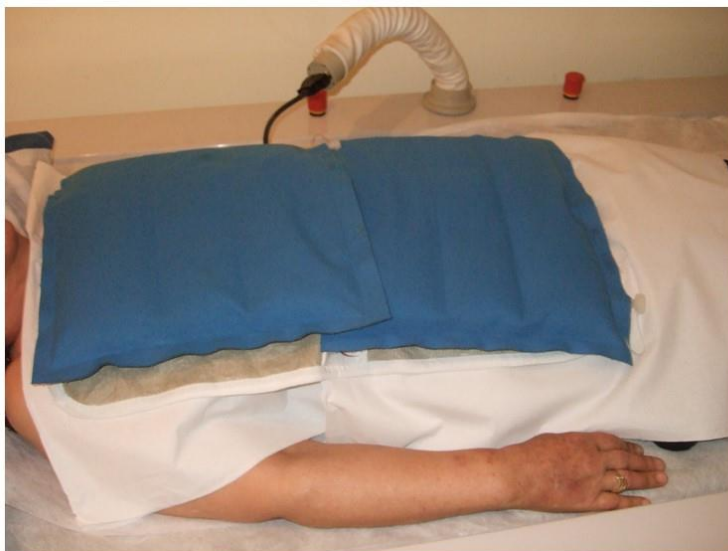Complete response of the chest wall disease



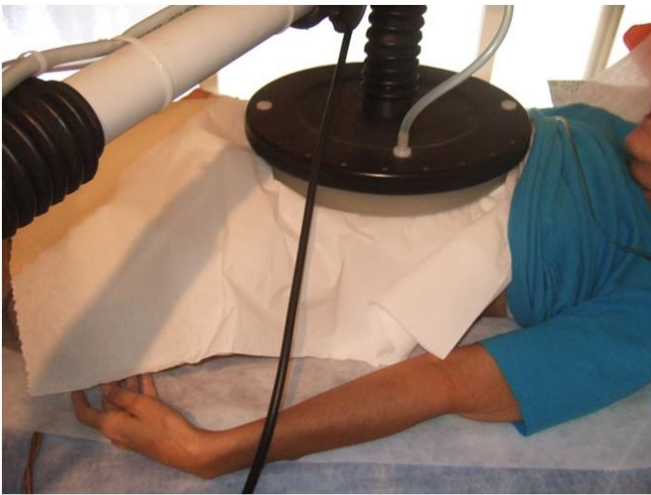Pancreatic cancer, intra-abdominal spread, liver metastasis.



The above patient after treatment with EHY-3000 to the whole abdomen and with EHY-2000 to the liver area.



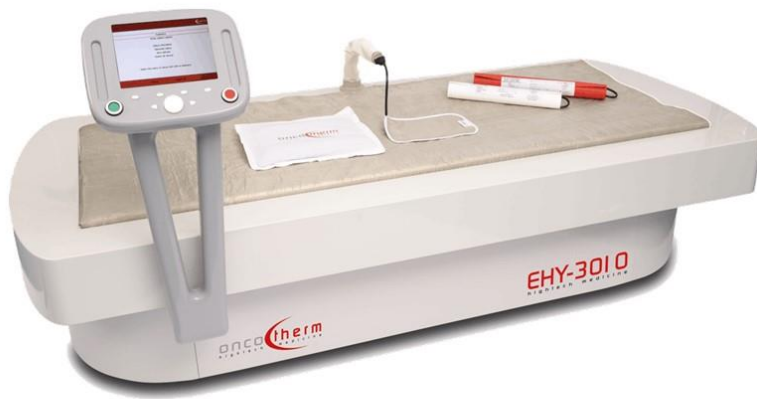Treatment to the chest, abdomen and pelvis with EHY-3000



Localized treatment to liver area with EHY-2000



EHY-2000 Treatment to a localized area up to 30 cm in diameter



EHY-2000 Treatment to a localized area up to 30 cm in diameter