Potential Application of Neoadjuvant Chemotherapy Plus Modulated Electro-hyperthermia (mEHT, trade name: Oncothermia) Among Patients With Advanced Cancer: Retrospective Clinical Analysis Of Single Hospital Experiences

Joon-Hee Kim, Min-Young Kim, Hee-Young Kim

Cancer Hyperthermia Research Center, Oasis Clinical Care Hospital (Kwangju, Republic of Korea)
E-mail: mdkimjh@naver.com

Presented at the 37th ICHS, Thessaloniki

Cite this article as:

Kim JH. et al. (2019): Potential Application of Neoadjuvant Chemotherapy Plus Modulated Electro-hyperthermia (mEHT, trade name: Oncothermia) Among Patients with Advanced Cancer: Retrospective Clinical Analysis of Single Hospital Experiences, Oncothermia Journal 27: 62- 75
www.oncotherm.com/sites/oncotherm/files/2019-10/Potential_Application_of_Neoadjuvant.pdf

Introduction

Despite aggressive local therapy, patients with locally advanced cancer are at significant risk for local recurrences and systemic metastases. The risk of local recurrence after operation is largely dependent on clinical stage. The predominant cause of metastatic recurrence is occult micrometastases. More effective treatment methods are therefore needed for local and systemic controls. For these purposes, hyperthermia is limitedly applied to locally advanced sarcoma or high risk peritoneal carcinomatosis patients with perioperative chemotherapy. But because of some side effects and low patient compliance neoadjuvant chemotherapy with classic hyperthermia has limitations. In preclinical and clinical data modulated electro-hyperthermia(mEHT) not only suppress local tumor growth but also demonstrate immunologic effects at distant sites with negligible side effects. For this reason, there is interest in combining locoregional mEHT and systemic chemotherapy before definitive surgical treatment.

Objectives

The primary objective is whether the neoadjuvant chemotherapy plus mEHT in patients with various locally advanced cancer is feasible. The secondary objective is evaluation of safety and side effects of this treatment.

Material/Methods

This is a single hospital, observational and retrospective clinical study. We reviewed the medical records of all patients who underwent mEHT at Oasis Cancer Hyperthermia Research Center between January 2017 and July 2019. The feasibility of patients treated with neoadjuvant chemotherapy plus mEHT as well as safety and side effects were investigated. The chemotherapy regimens differed from cancer types and the university hospitals they treated.

Results

Data from 203 eligible patients were collected. The number of patients by cancer types were 101 breast, 26 stomach, 13 thyroid, 12 colon, 10 rectum, 9 lung, 8 ovary, 6 liver, 5 cervix, 5 sarcoma, 5 pancreas and 3 oesophageal cancer patients respectively. Among them 21 patients showed receiving neoadjuvant chemotherapy with mEHT treatment. The majority of these patients had stage III or IV disease at diagnosis. The number of patients by cancer types were 11 breast, 4 rectum, 3 stomach, 2 ovary and 1 colon cancer patients. No patients showed progressive disease during this treatment and all of them could done operation. Two breast cancer patients showed complete response. The side effects were tolerable and compatible with the type of chemotherapy regimen they received. No additional side effects related to the treatment of mEHT was noted.

Conclusion

There is no clinical trial whether neoadjuvant mEHT with chemotherapy treatment of localized advanced cancer feasible. Our retrospective analysis demonstrates that this treatment method can be given safely before operation to patients with locally advanced cancers. Although patient numbers were small all 21 patients could receive operation without disease progression. We believe that this neoadjuvant hyperthermic chemotherapy can be offered to patients with locally advanced cancers. Further studies are needed to evaluate the patient survival.

오아시스 요양병원 닥터. 오아시스

Potential Application of Neoadjuvant Chemotherapy Plus modulated Electro-hyperthermia(mEHT, trade name:Oncothermia) Among Patients With Advanced Cancer: Retrospective Clinical Analysis Of Single Hospiatal Experiences

Joon-Hee Kim*, Min-Young Kim, Hee-Young Kim

Cancer Hyperthermia Research Center, Oasis Clinical Care Hospital*

(Kwangju, Republic of Korea)

E-mail: mdkimjh@naver.com

오아시스 요양병원 닥터. 오아시스

Advanced Cancers; Problems

- Early systemic micrometastasis in some cancers correlate with poor long-term survival(LTS) and quality of life(QOL)*
- High locoregional recurrences negatively impact both LTS and QOL

*N Engl J Med 2009; 361:653-663

NACT*; Scientific Background

- Preoperative chemotherapy ("neo-adjuvant chemotherapy," NACT) more beneficial than postsurgical adjuvant chemotherapy (ACT)
  - better overall survival (OS)
  - improve and/or optimize the surgical approach
  - monitor apparent response to adjust the specific regimen
  - Easy to perform phase II trials or to identify biomarkers
- Enough evidences?

NACT*; Neoadjuvant Chemotherapy

오아시스 요양병원 닥터 오아시스

Possible benefits of NACT

Potential benefit	Proven with high levels of evidence?
Prolongation of overall survival	No
Optimize surgical approach	Yes
Modify chemotherapeutic regimen	No
Add further chemotherapy	No
Phase II testing of new drugs, new regimens, or compare regimens	Partially
Identify new biomarkers of response or toxicity	No

JNCI Monographs, 2015, 51, 36-30

오아시스 요양병원

닥터 오아시스

mEHT*; Scientific Background

- Direct local cytotoxic effects and indirect systemic immunologic effects
- Few side effects and good patient compliance
- Expect synergistic effects when doing with NACT

*modulated Electro-hyperthermia(mEHT, trade name:Oncothermia)

오아시스 요양병원

닥터 오아시스

mEHT; Korean Situations

- Use mEHT at large numbers of small integrative oncology hospitals but small numbers at large academic hospitals including Univ. Hospitals
- Barriers obtaining clinical data, doing clinical trials
- May have great potential in collecting data or performing clinical trials

오아시스 요양병원 닥터. 오아시스

NACT + mEHT; Purposes

- Feasibility of NACT + mEHT among patients with advanced cancer by checking efficacy and TEAE*
- Identification of available cancers for NACT + mEHT research in Korea

*TEAE; treatment-emergent adverse event

오아시스 요양병원 닥터. 오아시스

2016.12.20 established

Types of Cancer

- 70~80 patients admission
- Major cancer types; breast, stomach, thyroid, colon-rectum and uterus

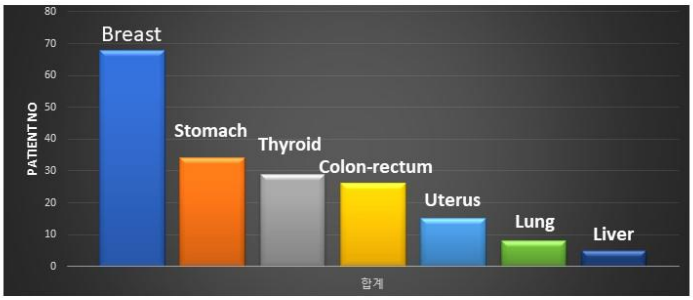

Admission numbers, 2017

오아시스 요양병원 닥터 오아시스

Oasis Cancer Care Program

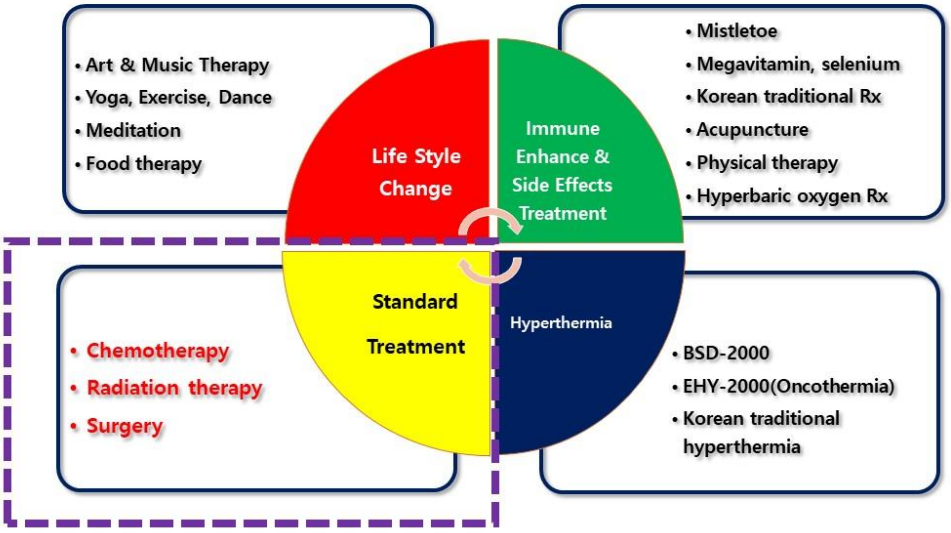

오아시스 요양병원 닥터. 오아시스

Multidisciplinary Integrative Medical Care

오아시스 요양병원 닥터. 오아시스

Cancer Hyperthermia Research Center

오아시스 요양병원 닥터. 오아시스

Life Style Change

오아시스 요양병원 닥터. 오아시스

Study Design

- Retrospective chart review the patients who received mEHT from Jan. 1, 2017, to July 31, 2019
- Reviewed through the hospital's electronic medical record database
- All clinical encounters, basic demographic information, surgery and pathology reports, and treatment history
- Inclusion criteria: age ≥18 years, mEHT treatment No ≥ 12, who intend surgery when initially admit

NACT + mEHT; Patient Characteristics

mEHT Tratment

- 203 patients
- Age; 51 ± 9 yrs
- Sex; male, 148 *vs* female 53
- 101 breast, 26 stomach, 13 thyroid, 12 colon, 10 rectum, 9 lung, 8 ovary, 6 liver, 5 cervix, 5 sarcoma, 5 pancreas and 3 oesophageal cancer

NACT + mEHT

- 21 patients
- Age; 48 ± 6 yrs
- Sex; male, 16 *vs* female 5
- 11 breast, 4 rectum, 3 stomach, 2 ovary and 1 colon cancer

오아시스 요양병원 닥터. 오아시스

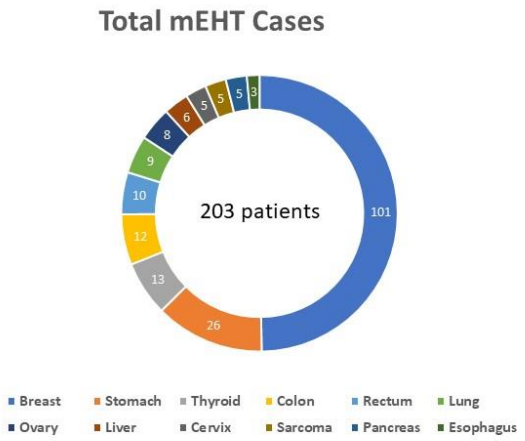

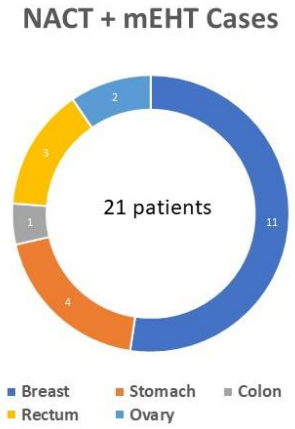

오아시스 요양병원 닥터 오아시스

Concurrent Treatment

Types	Chemotherapy	Radiation Therapy	Condition
Breast	AC[1], DC[2], DCF[3]	No	≥5cm, invading into skin/chest wall, axillary lymph nodes(+)
Rectum	CAPEOX[4], FOLFOX[5]	Yes	T staging, location
Stomach	XELOX[6], FOLFOX	No	Mesentery, para-aortic lymph node , major vessel involvements, surrounding organs
Ovary	CT[7], CTB[8]	No	Peritoneal carcinomatosis, Debulking surgery
Colon	FOLFOX	No	Pericolic adipose tissue(+), surrounding organs

AC[1];doxorubicin+cyclophosphamide, DC[2];docetaxel + cyclophosphamide, DCF[3]; docetaxel + cyclophosphamide+ 5-FU, CAPEOX[4];capecitabine+oxaliplatin, FOLFOX[5]; 5-FU+oxaliplatin,XELOX[6];capecitabine+oxaliplatin, CT[7];carboplatin+paclitaxel, CTB[8]; carboplatin+paclitaxel+bevacizumab

오아시스 요양병원 닥터 오아시스

Example; Breast Cancer Case

NACT + mEHT; pCR Case

- F/72; Jul, 2017 -, axillary lymph nodes(+) triple-negative left breast cancer, AC + docetaxel sequencing NACT

Stage (cT2cN1M0)

*MMG/Breast sono('17.6.15): 2.4x2.2x3.0 cm irregular mass in Lt 12h N7cm, Three borderline LNs in Lt Ax level I-II,
*o/s C-CT('17.6.23): Lt. breast cancer and mildly prominent axillary LNs, GB and far distal CBD stone.
*BS('17.6.28): NED
*PET('17.6.28): Lt. breast cancer, Possible metastatic LNs in the Lt. axilla level I
-->LA breast ca, cT2N1M0, IIB로 preOP AC#4 (17.7.5-17.9.13)
#4후 C-CT(17.9.14): Much decreased size of left breast cancer and ipsilateral axillary LNs
-->docetaxel #4 (17.10.11-17.12.15)

Breast, left, "12H", needle biopsy:
INVASIVE DUCTAL CARCINOMA with
1) nuclear grade: 3/3
2) histologic grade: III/III
3) DCIS component: not identified
4) maximum diameter of invasive carcinoma: 11 mm
IHC :
- Estrogen Receptor : Negative
- Progesterone Receptor : Negative
- P53 : Positive in >75%
- Her-2 : Negative (-/3)
- Ki-67 :Positive in 30%

SNUH Pathology Report

Surgical Pathology Findings

2018.1.12 BCS+ SLNB, lt (post NCT): ypT0, ypN0/4
pCR

2018.1.12 BCS+ SLNB, lt (post NCT)
postop 1st visit

path : Breast, left, breast conserving surgery:
NO RESIDUAL TUMOR (see note2)
- Post-neoadjuvant chemotherapy status
- Previous pathology report: S 17-32578 (INVASIVE DUCTAL CARCINOMA)
- Microcalcification: absent
- Lymphatic emboli: absent
- Vascular emboli: absent
- Surgical margins:
  superior margin: clear
  inferior margin: clear
  medial margin: clear
  lateral margin: clear
  superficial margin: clear
  deep margin: clear
- Number of metastatic lymph nodes: 0
- Number of examined lymph nodes: 4
  (sentinel LN#1-#2, 0/4 (Fro#1-2); "Lt. axillary tissue", 0/0)

SNUH Pathology Report

오아시스 요양병원

NACT + mEHT; Efficacy*

Types(No)	complete remission	partial remission	stable disease	progressive disease
Breast(10)	2	5	3	0
Rectum(4)	0	4	0	0
Stomach(3)	0	1	2	0
Ovary(2)	0	2	0	0
Colon(1)	0	1	0	0

by *RECIST 1.1

오아시스 요양병원

NACT + mEHT; TEAE*

- Tolerable TEAE
- Different type of toxicities depend on chemotherapy protocols
- No grade 3 or higher non-hematologic toxicities**
- Mild mEHT-related toxicities less than grade 2
  - Blister, pain, erythema, general weakness
  - Chest discomfort due to pressure in breast cancer patients

*TEAE; treatment-emergent adverse event
** National Cancer Institute Common Toxicity Criteria, 3.0 v

오아시스 요양병원

닥터 오아시스

NACT + mEHT; Conclusions

- Breast, rectal cancer; majority
- High intention to surgery rate
- Tolerable TEAE as similar as when doing conventional NACT
- May reduce local recurrences and early micrometastasis
- Future data collecting with other mEHT using hospitals for further clinical study in academic hospitals

오아시스 요양병원

Thank you

닥터 오아시스

감사합니다.