

**Complete responses after hyperthermic ablation by  
ultrasound guided high intensity focused ultrasound  
(USgHIFU) plus systemic chemotherapy (SC) for locally  
advanced pancreatic cancer**

**Vidal-Jove Joan<sup>1</sup>, Garcia Bernal Marta<sup>2</sup>, Perich Eloi<sup>1</sup>, Alvarez del  
Castillo Mauel<sup>3</sup>**

(1) Surgical Oncology HIFU Unit, (2) Pediatric and (3) Medical Direction Departments  
Hospital Universitari Multua Terrassa (HUMT), Barcelona, Spain

Pl. Dr. Robert, 5

08221 Terrassa, Barcelona Spain

[www.mutuaterassa.cat](http://www.mutuaterassa.cat)

Address correspondence to Vidal-Jove Joan: [jvidal@mutuaterassa.es](mailto:jvidal@mutuaterassa.es)

Published: <http://www.hindawi.com/cpis/medicine/2013/586769/>

# **Complete Responses after systemic chemotherapy (SC) plus hyperthermic ablation by high intensity focused ultrasound (HIFU) for locally advanced pancreatic cancer**

## ***Abstract***

We describe results in unresectable pancreatic tumors treated with USgHIFU hyperthermia ablation plus adjuvant chemotherapy. **Materials and Methods:** 32 cases of non resectable pancreatic tumors were treated from March 2010 to March 2012, and all of them underwent systemic chemotherapy. Clinical responses (thermal ablation achieved) were measured by image techniques. They were 23 Stage III cases and 9 Stage IV cases. Complications were also analyzed.

**Results:** Clinical responses (ablation obtained) were 82% in all cases, sustained at 8 weeks of the procedure. We obtained 8 complete responses (25%) at the end of the combined treatment, 7 from stage III patients and 1 from stage IV. Major complications included severe pancreatitis with GI bleeding (1), skin burning grade III that required plastic surgery (2). No deaths were registered. Median Survival was 12.5 month (6 mo – 2.5 year)

**Conclusion:** HIFU plus SC is a potentially effective and safe modality for the treatment of unresectable pancreatic cancer.

## ***Keywords***

Pancreatic cancer, High-intensity focused ultrasound ablation, HIFU, Gemcitabine, Chemotherapy

## ***Introduction***

Despite continuous scientific advances in the field of oncology, pancreatic cancer has a poor prognosis nowadays. A significant part of cases are considered unresectable at diagnosis due to late detection of the disease or to invasion of great vessels surrounding the tumor [1]. Therefore, treatments with chemotherapy and in lesser grade radiotherapy are the only tools suitable to be offered to the patients with locally advanced disease [2]. Overall survival is around 6-10 months in stage III patients and only 3-6 months for stage IV cases [1].

At present, there is no ablative technique suitable for pancreatic lesions. High Intensity Focused Ultrasound (HIFU) is a minimally invasive surgical technique that has proven to improve the local control in different types of tumors. Several studies in animals and humans have shown the efficacy of this technique to cause a coagulative necrosis than is able to diminish or even ablate tumoral masses. Previous reports of the treatment of pancreatic masses by HIFU have been published recently, specially underlining its role as a good concomitant treatment associated to gemcitabine based chemotherapy protocols.

The HIFU Unit in Hospital Universitari Mutua Terrassa was established in 2008. First cases were exclusively uterine fibroid tumors. Since January 2010 a wide variety of malignant tumors had been treated at our institution. The HIFU device at this Unit is Ultrasound guided JC 200 device from HAIFU Chongqing (China). The purpose of this study is to evaluate retrospectively the results of HIFU treatment in a group of advanced pancreatic cancer patients managed in our center.

## ***Material and methods***

From March 2010 to March 2012 thirty-two cases of non-resectable pancreatic tumors due to locally advanced disease were treated with HIFU in our institution. Most patients were referred from the oncology or surgery departments of different Spanish hospitals, although three of them came from other European institutions. All of them had a pathology confirmed diagnosis of pancreatic cancer and underwent systemic chemotherapy with a Gemcitabine based combination prior to HIFU treatment. Patient's ages ranged from 32 to 79 years old (median= 63). They were 23 Stage III cases and 9 Stage IV cases, according to TNM International classification. HIFU treatment was administered at least 4 weeks after chemotherapy was discontinued. Previous Doppler color Ultrasound was obtained and simulation procedure was performed in all cases. Two cases were excluded from the initial selection because the ultrasound image was not able to

obtain a good identification of the tumoral mass and therefore treatment was not performed. All patients were under general anesthesia to manage the procedure-associated pain and to obtain a better control of the respiration movements during treatment.

In thirty patients HIFU treatment was performed only once, but in two cases the procedure was repeated 2 months later to ablate the remaining tumor. The median intensity of treatment was 350 Watts, which corresponds to a median temperature of 70 degrees Celsius. The HIFU device in Clinical responses (thermal ablation achieved of the pancreatic tumor) were measured at 4, 8, 12 and 16 weeks by CT Scans, MRI and PET image techniques, all of them available at our hospital. Response was considered positive if an ablation of more than 60% of the tumoral mass was achieved. Two experienced radiologists reviewed results. Patients with poor hematologic conditions, previous radiotherapy treatment or poor Karnofsky's index were excluded. Responses obtained were measured under RECIST criteria. The complications were also analyzed.

## ***Results***

Clinical responses in terms of ablation obtained were 82% in all cases, confirmed and sustained at 8 weeks of the procedure. We obtained 8 complete responses (25%) at the end of the combined treatment of HIFU plus systemic chemotherapy, 7 from stage III patients and 1 from stage IV. The longest survival since treatment is 2.5 year. At the time of this writing, twenty-two patients had died and ten were alive. The overall median survival time was 12.5 months (range, 6–30 months). Patients died as a result of cachexia, hepatic dysfunction caused by liver metastases untreated with high-intensity focused ultrasound, peritoneal carcinomatosis or other systemic progression of the disease.

Major complications were registered including severe pancreatitis with GI bleeding (one case), skin burning grade III that required plastic surgery (2 cases). No deaths were registered due to the procedure. None of the patients needed emergency surgical procedures due to complications. During the hospital stay, no signs of tumor hemorrhage, large blood vessel rupture, or gastrointestinal perforation were detected in any patient. No dilatation of the common bile duct or pancreatic duct was visible at follow-up imaging. There was no evidence of post-interventional peritonitis, or jaundice in any patient during the follow-up period.

## ***Discussion***

US-guided HIFU is a feasible technique with no mortality, low morbidity and promising results. At present, there are several ablation techniques employed to treat tumors in different locations. Radiofrequency, cryotherapy, ethanol injection, or embolisation are considered for tumors in several locations except pancreas tumors. Recently, several papers have emphasized the use of HIFU for pancreas tumors [3, 4, 5]. Anatomical locations of these types of lesions preclude the use of the above-mentioned procedures but allow the treatment with HIFU. In our study, the high percentage of responses obtained in terms of meaningful ablation achieved (82%) confirms this assumption. Hyperthermic ablation techniques role in cancer patients need to be defined.

The increased prevalence of pancreatic tumors as well as the better results obtained with the combination of chemotherapy plus best supportive care of these patients, raise the issue of cytoreductive treatments addressed to control loco-regional progression of the disease. Ablation techniques in those cases, and HIFU among all of them, may play an interesting role, supported by its results and low morbidity obtained. In our study no significant morbidity was added to decrease the quality of life on our patients. Longer survival compared with the statistics reported in the literature reinforces our tumor ablation program with HIFU.

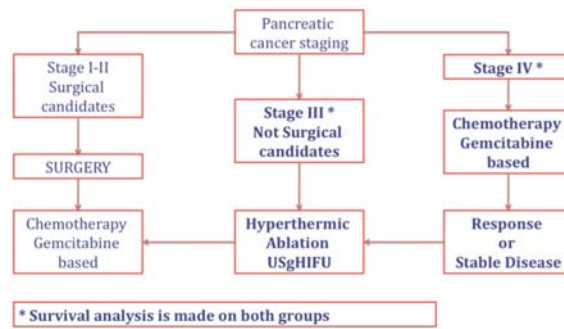
Where surgery does not arrive. There is a subgroup of patients that can be specially benefited with HIFU ablation techniques [6]. Patients with stage III tumors due to minimal vascular invasion that are not candidates to surgical resection may become free of disease after HIFU ablation. In our results 7 patients from our group of Stage III patients achieved a complete response, 4 of the still alive at the writing of this article. Need for multicentric studies: reporting, assessment and duration of response remain as controversial issues that need to be clarified in the coming studies.

There are difficulties to analyze percentage of response with tumors in the pancreas head. PET Scans are still difficult to evaluate when SUV is in its limits. In those cases inflammation and tumor recurrence are not clearly distinguished. Because 90% of the patients with pancreas tumors are diagnosed with regional or distant disease and do not have effective modalities of treatment, we are very encouraged with the results of our experience. We suggest that HIFU is a feasible, safe and effective technique to control local disease in stage III pancreas tumors that need to be tested in randomized clinical trials.

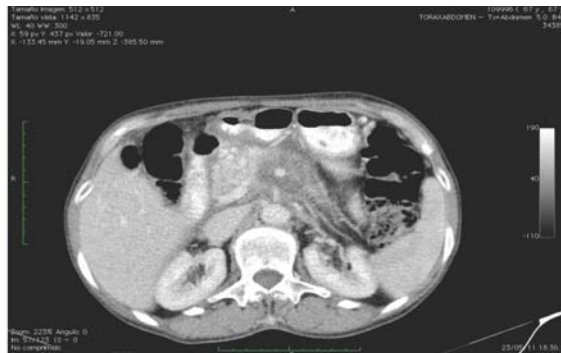## References

1. Siegel R, Naishadham D, Jemal A. Cancer statistics, 2012. *CA Cancer J Clin* 2012; 62:10-29
2. Cunningham D, Chau I, Stocken DD, Valle JW, et al. Phase III randomized comparison of gemcitabine versus gemcitabine plus capecitabine in patients with advanced pancreatic cancer. *J Clin Oncol* 2009;27:5513-5518
3. Feng Wu, Zhi-Biao Wang, Hui Zhu, et al.. Feasibility of US-guided High-Intensity Focused Ultrasound Treatment in Patients with Advanced Pancreatic Cancer: Initial Experience. *Radiology* 2005; 236:1034–1040
4. Jae Young Lee, Byung Ihn Choi, Ji Kon Ryu, et al. Concurrent Chemotherapy and Pulsed High-Intensity Focused Ultrasound Therapy for the Treatment of Unresectable Pancreatic Cancer: Initial Experiences. *Korean J Radiol* 2011;12(2):176-186
5. Zhao H, Yang G, Wang D, Yu X, et al. Concurrent gemcitabine and highintensity focused ultrasound therapy in patients with locally advanced pancreatic cancer. *Anticancer Drugs* 2010;21:447-452
6. Franco Orsi, Lian Zhang, Paolo Arnone, et al. High-Intensity Focused Ultrasound Ablation: Effective and Safe Therapy for Solid Tumors in Difficult Locations. *AJR* 2010; 195:W245–W252

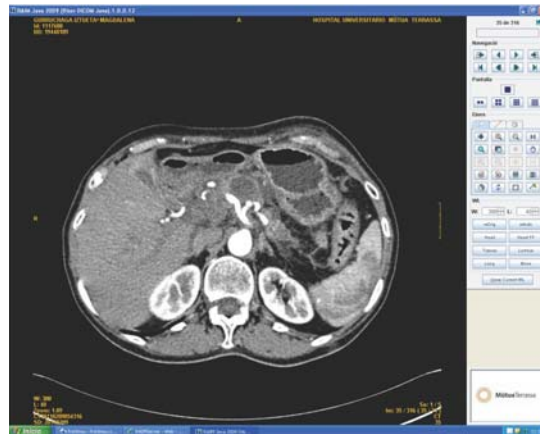
## Figures



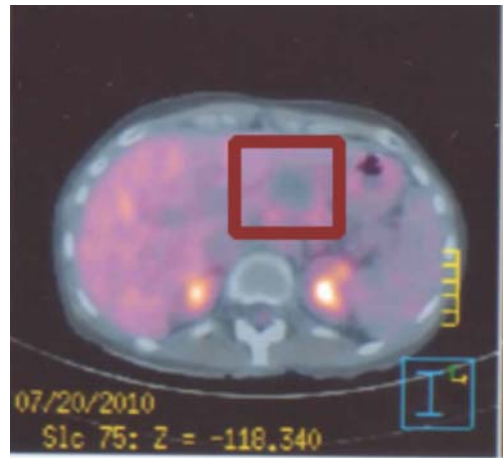
**Figure 1.** Pancreas cancer clinical pathway




**Figure 2.** CT scan of tumor ablated in pancreas body preserving superior mesenteric artery



**Figure 3.** CT scan of tumor ablated in pancreas body above celiac trunk



**Figure 4.** Pet scan of the Figure 2. case showing complete response on the tumor site



**Figure 5.** The US-guided HIFU device JC 200