Breast Cancer Series Treated with Modulated Electro-Hyperthermia (mEHT) a single center experience

Erika, Borbenyi[1], Judit Desfalvi[1], Gyongyver Szentmartoni[1], Tamas Garay[1,2], Reka Mohacsi[1], Mariann Kvansika[1], Marcell A. Szasz[1], Magdolna Dank[1]

[1] Cancer Center, Semmelweis University, Budapest, Hungary

[2] Faculty of Information Technology and Bionics, Pazmany Peter Catholic University, Budapest, Hungary

Presented at 36th ICHS, Budapest, 2018

Cite this article as:

Borbenyi E. (2018): Breast Cancer Series Treated with Modulated Electro-Hyperthermia (mEHT) a single center experience; Oncothermia Journal 24:109-121

www.oncothermia-journal.com/journal/2018/Breast_cancer_series.pdf

Breast Cancer Series Treated with Modulated Electro-Hyperthermia (mEHT) -- a single center experience

Erika, Borbenyi[1], Judit Desfalvi[1], Gyongyver Szentmartoni[1], Tamas Garay[1,2], Reka Mohacsi[1], Mariann Kvansika[1], Marcell A. Szasz[1], Magdolna Dank[1]

[1]Cancer Center, Semmelweis University, Budapest, Hungary

[2]Faculty of Information Technology and Bionics, Pazmany Peter Catholic University, Budapest, Hungary

Background

mEHT is a relatively new kind of hyperthermia in oncology. It is a further development of the conventional heating methods.

Aim

Our objective in this presentation is to summarize our knowledge about the utilization of mEHT therapy from the practical perspective in breast cancer and summarize our experience in our breast cancer patients treated with mEHT.

Methods

Thirteen patients with advanced breast cancer (12 invasive ductal carcinoma and 1 postirradiation angiosarcoma) were treated in a 20 months period at the Cancer Center of Semmelweis University, with the instruments EHY-2000 and EHY-2030 (Oncotherm Ltd., Budaörs, Hungary). One patient also developed pancreatic cancer, and one patient only attended one session, thus, these were omitted from further analysis.

Results

Two patients were treated for locally advanced disease in a neoadjuvant fashion. The rest of patients were node positive and/or metastatic. The most common metastatic sites were lymph nodes (9), bone (5), liver (4) and lung (4) with cutaneous involvement (2). The average time in treatment was 11.2 weeks (range: 2.4-23.2). Various neoadjuvant and first-line chemotherapeutic protocols were applied, mostly platinum and taxane containing regimina, but also capecitabine, tegafur, mitomycin C, gemcitabine, lapatinib were administered. A two-week break in therapy was necessary in five cases due to local discomfort (2), nausea and weakness (2) and hydrothorax (1). The patients with primary systemic therapy continued with surgery and finished treatment, one patient stopped at week 20 due to inflammed port and eight patients progressed in an average 9.7 weeks.

Discussion

Complementary mEHT treatment of breast cancer patients is feasible and easy to administer. Most durable responses were seen in skin metastases and/or bone and decreasing time with lung and liver involvement. Most important favoring prognostic factors were lower stage and less number of metastases (oligometastatic status with maximally two distant metastatic sites). Younger age was a poor prognostic factor also accompanied with multiorgan metastases (3<).

Grant support: NVKP_16-1-2016-0042

Breast Cancer Series Treated with Modulated Electro-Hyperthermia (mEHT)

a single center experience

Borbényi E[1], Désfalvi J[1], Szentmártoni Gy[1], Garay T[1,2], Mohácsi R[1], Kvasnika M[1], Szasz AM[1], Dank M[1]

(1) Cancer Center, Semmelweis University, Budapest, Hungary

(2) Faculty of Information Technology and Bionics, Pazmany Peter Catholic University, Budapest, Hungary

Disclosures – conflict of interest

NONE

- M.D./Ph.D., pathologist
- Research funding
  - Hungarian Society of Medical Oncology (indirectly from Roche, Pfizer, GlaxoSmithKline)
  - Bristol-Myers Squibb
  - Hungarian National Research, Development and Innovation Office (NRDI Office), consultant for Oncotherm

- Head of Science - Cancer Center, Semmelweis University, Budapest, Hungary
- Secretary General, Hungarian Society of Senology
- Member of Board of Curators, International Academy of Pathology (IAP), Hungarian Division

Background and aim

- mEHT is a relatively new kind of hyperthermia in oncology.
- it is a further development of the conventional heating methods.

- Our objective in this presentation is to summarize our knowledge about the utilization of mEHT therapy from the practical perspective in breast cancer and summarize our experience in our breast cancer patients treated with mEHT.

Patients and methods

- Thirteen patients with advanced breast cancer
- 12 invasive ductal carcinomas
- 1 postirradiation angiosarcoma
- Pilot study for 20-month period
- instruments EHY-2000 and EHY-2030 (Oncotherm Ltd., Budaörs, Hungary)

- One patient also developed pancreatic cancer, and one patient only attended one session, thus, these were omitted from further analysis.

Postirradiation angiosarcoma

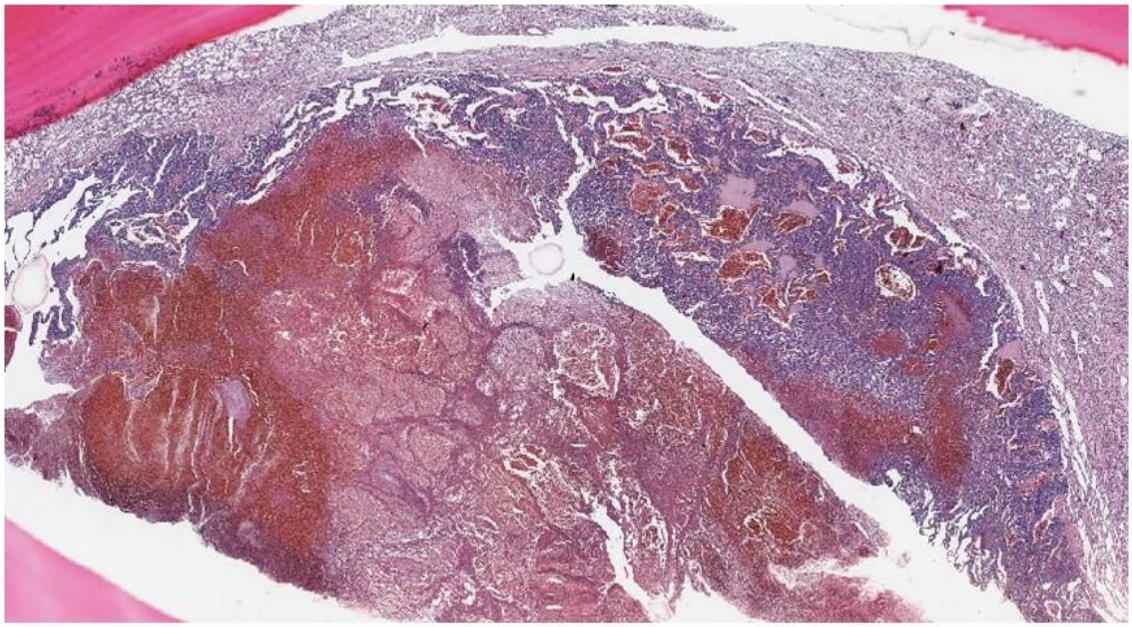

Postirradiation angiosarcoma

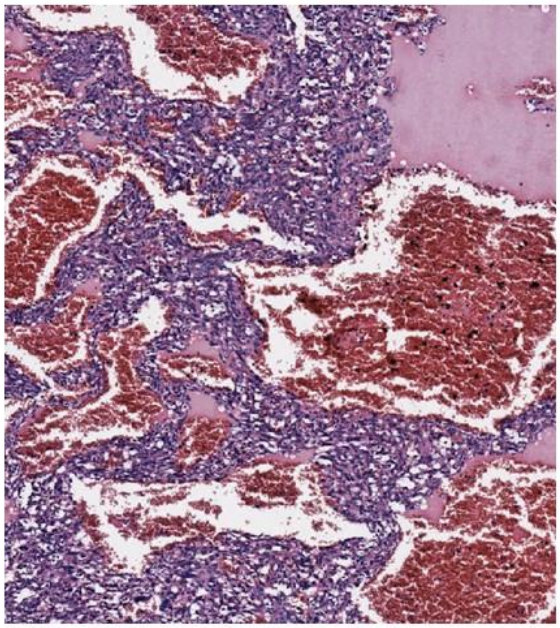

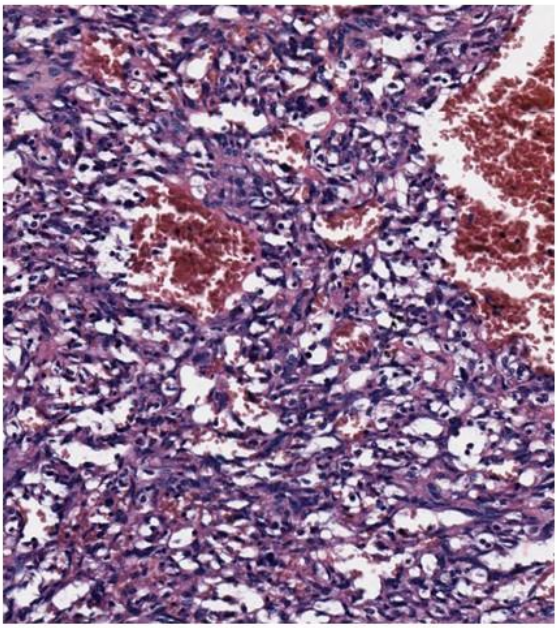

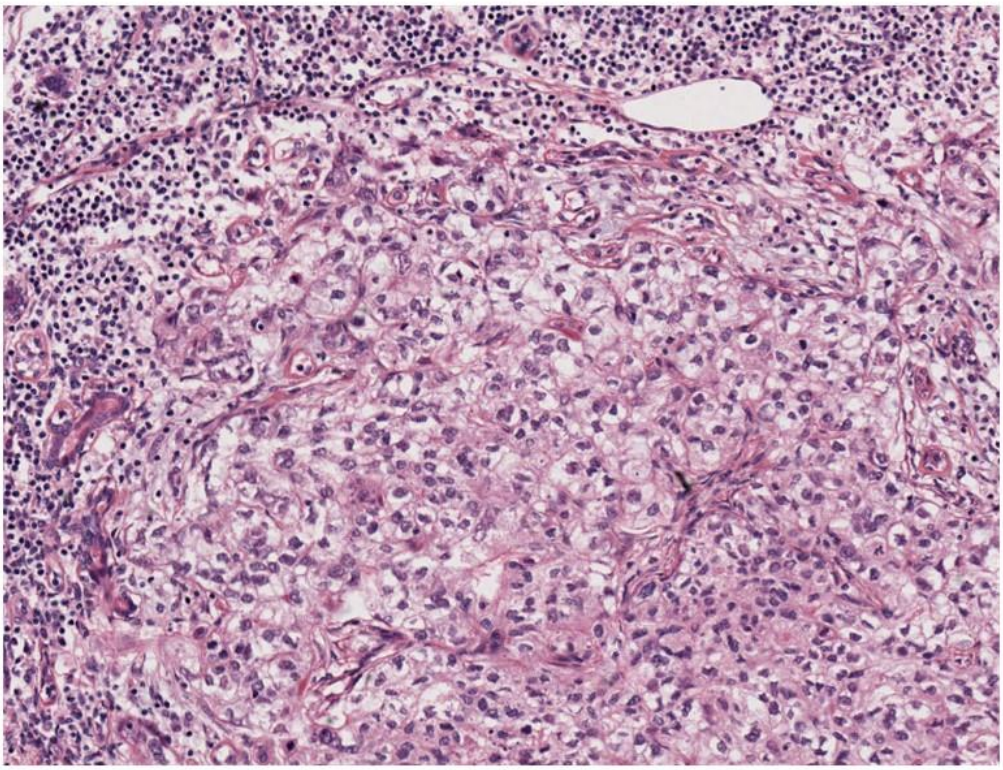

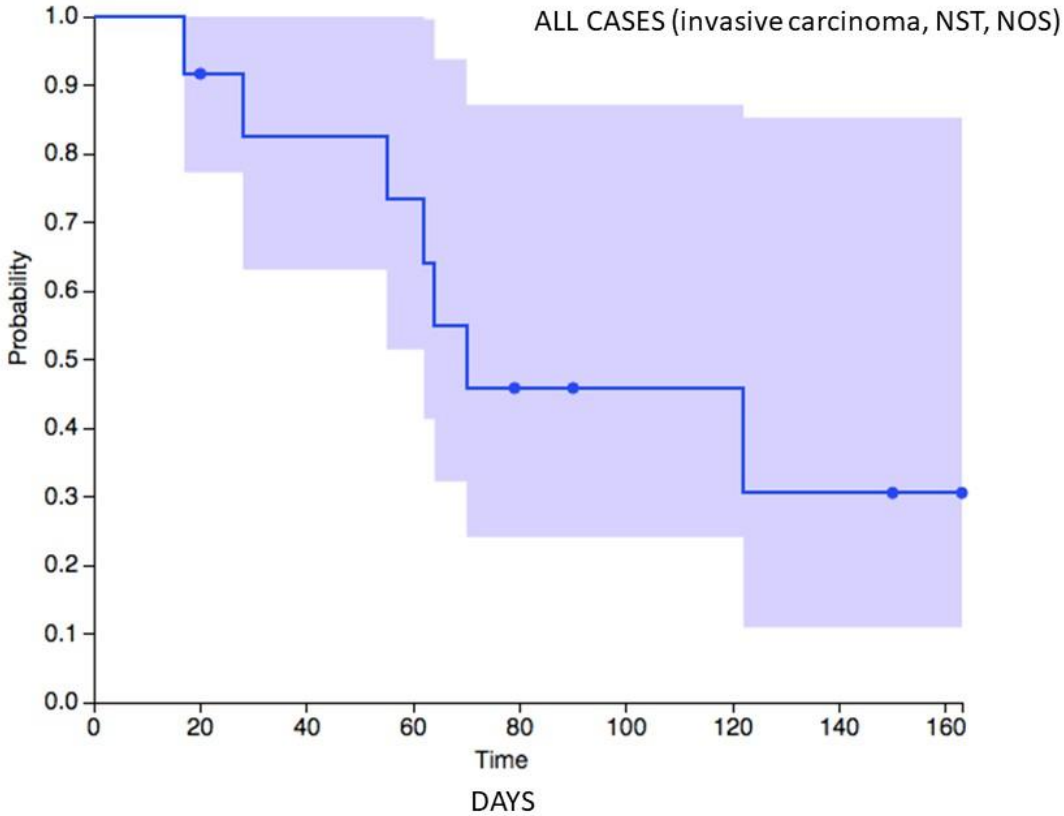
ALL CASES (invasive carcinoma, NST, NOS)
Probability
1.0
0.9
0.8
0.7
0.6
0.5
0.4
0.3
0.2
0.1
0.0
0
20
40
60
80
100
120
140
160
Time
DAYS

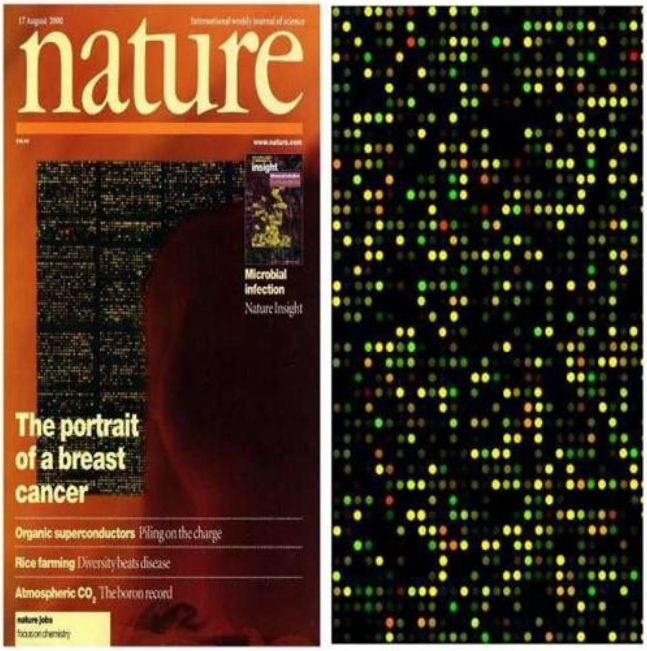

Breast cancer intrinsic biology and gene/protein expression

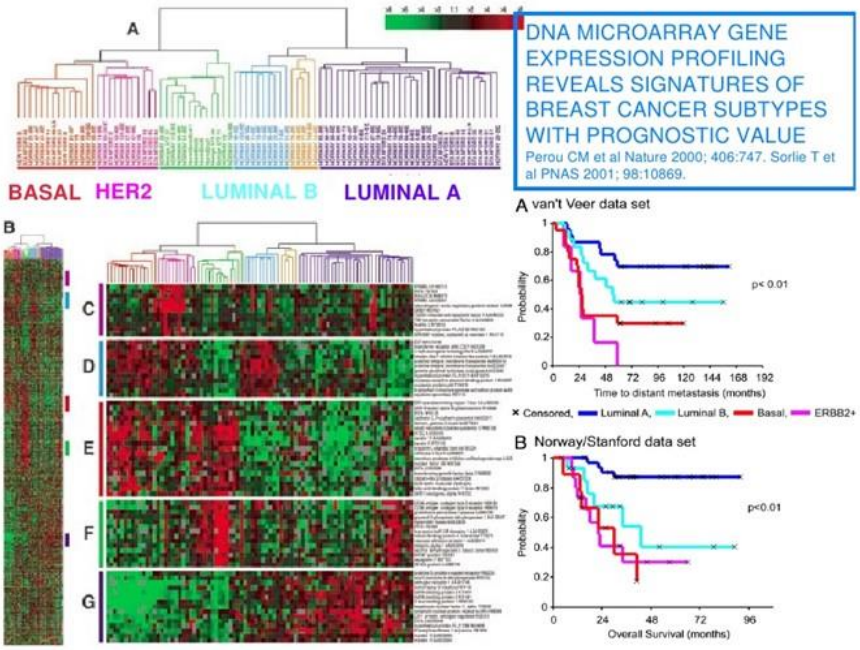

Perou, Nature 2000

Breast cancer intrinsic biology and gene/protein expression

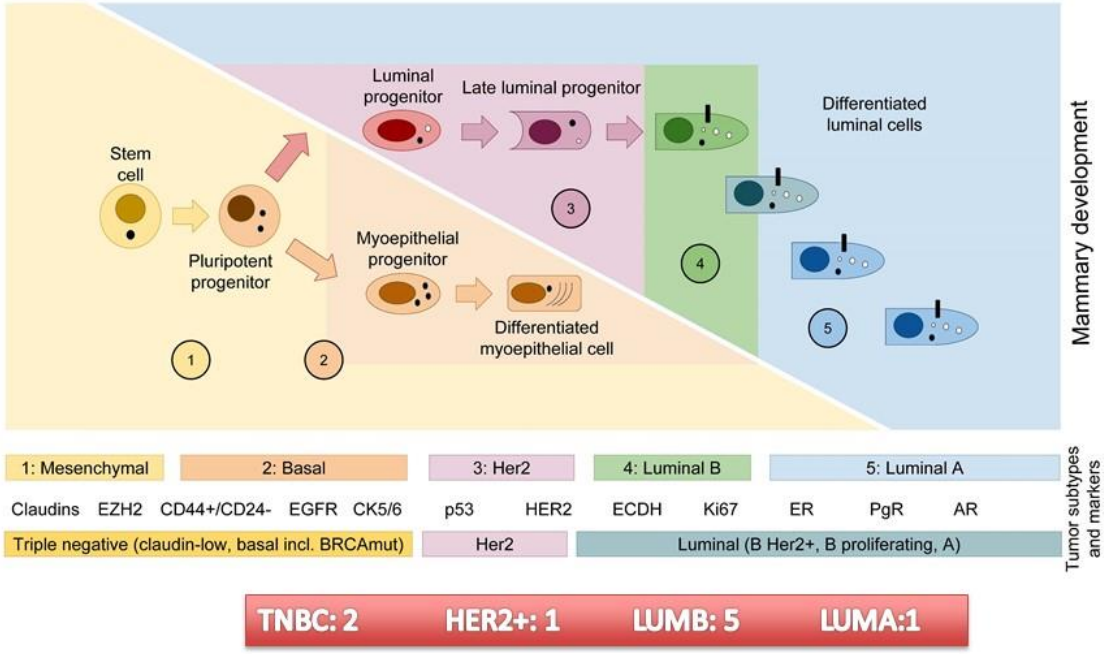

Madaras, Pathobiology 2016

Results

- Various neoadjuvant and first-line chemotherapeutic protocols were applied, mostly
- platinum and taxane containing regimina,
- but also capecitabine, tegafur, mitomycin C, gemcitabine, lapatinib were administered.
- A two-week break in therapy was necessary in five cases due to local discomfort (2), nausea and weakness (2) and hydrothorax (1).
- Two patients were treated for locally advanced disease in a neoadjuvant fashion.
- The patients with primary systemic therapy continued with surgery and finished treatment.

TNBC, neoadjuvant tx

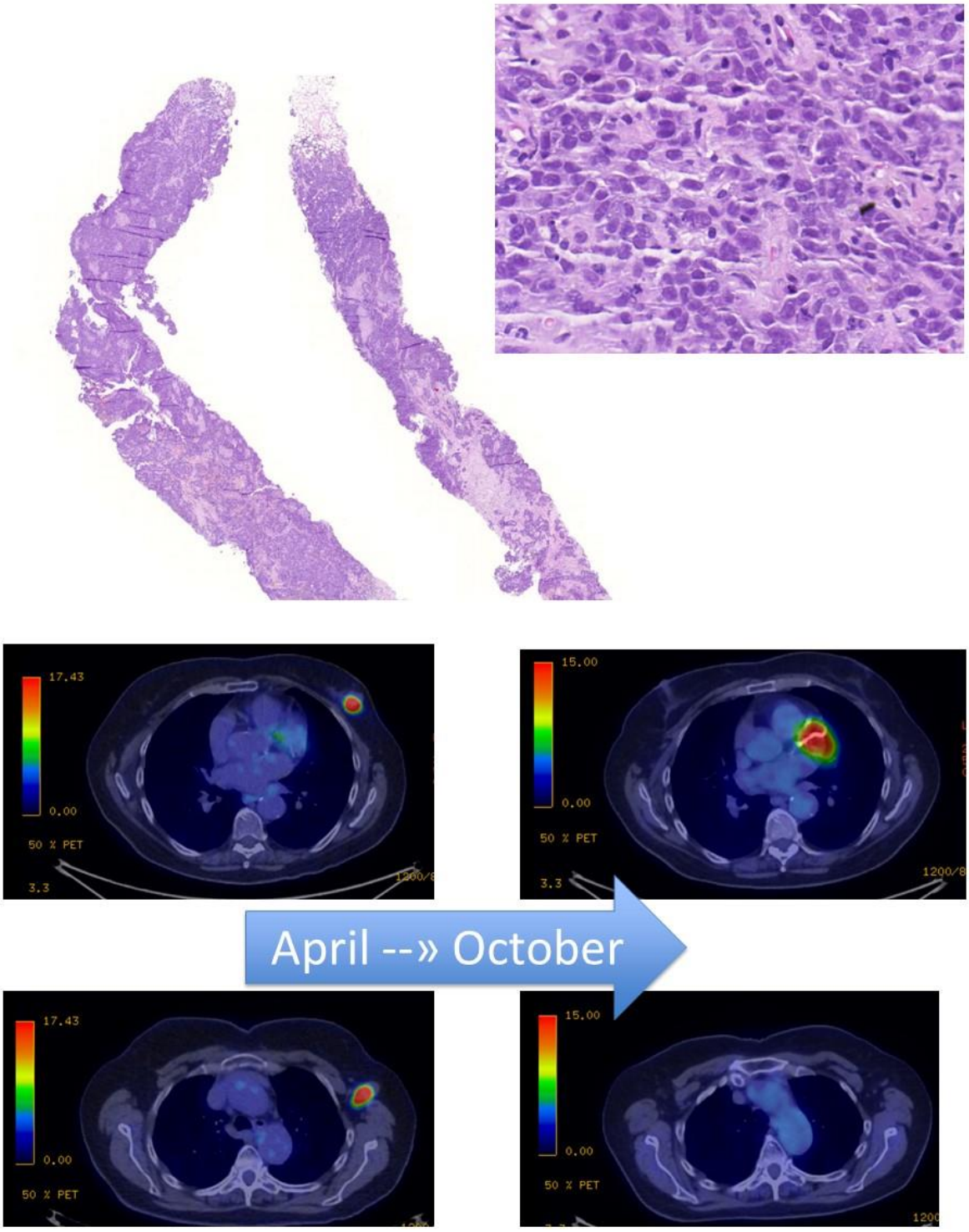

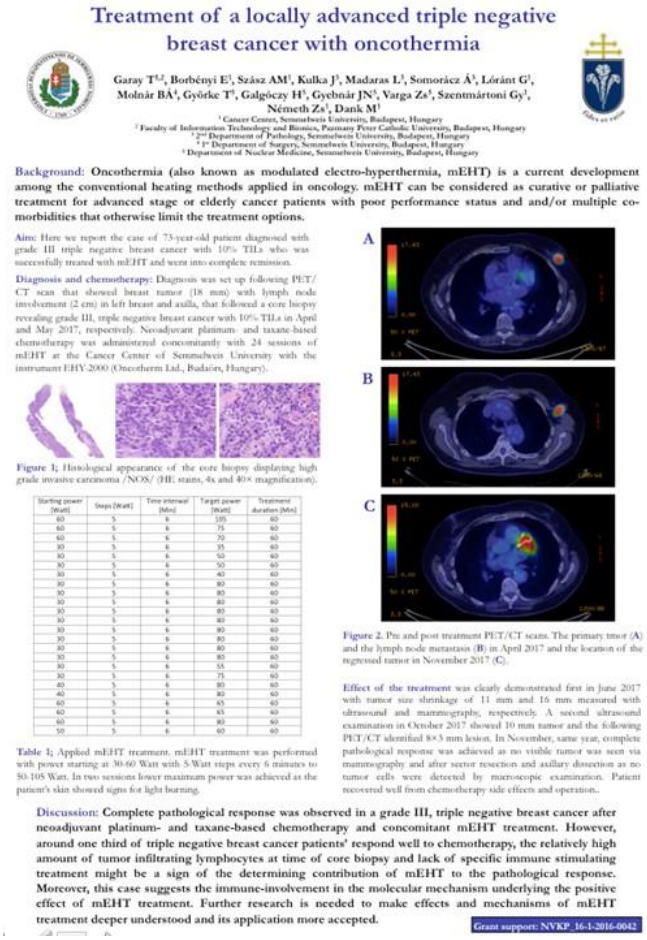

Treatment of a locally advanced triple negative breast cancer with oncothermia

Garay T[1,2], Borbényi E[1], Szász AM[1], Kulka J[3], Madaras L[4], Somorácz Á[5], Lóránt G[1], Molnár BÁ[4], Györke T[2], Galgóczy H[5], Gyebnár JN[5], Varga Zs[5], Szentmártoni Gy[1], Németh Zs[1], Dank M[1]

[1] Cancer Center, Semmelweis University, Budapest, Hungary
[2] Faculty of Information Technology and Bionics, Pazmany Peter Catholic University, Budapest, Hungary
[3] 2nd Department of Pathology, Semmelweis University, Budapest, Hungary
[4] 1st Department of Surgery, Semmelweis University, Budapest, Hungary
[5] Department of Nuclear Medicine, Semmelweis University, Budapest, Hungary

Background: Oncothermia (also known as modulated electro-hyperthermia, mEHT) is a current development among the conventional heating methods applied in oncology. mEHT can be considered as curative or palliative treatment for advanced stage or elderly cancer patients with poor performance status and and/or multiple co-morbidities that otherwise limit the treatment options.

Aim: Here we report the case of 73-year-old patient diagnosed with grade III triple negative breast cancer with 10% TILs who was successfully treated with mEHT and went into complete remission.

Diagnosis and chemotherapy: Diagnosis was set up following PET/CT scan that showed breast tumor (18 mm) with lymph node involvement (2 cm) in left breast and axilla, that followed a core biopsy revealing grade III, triple negative breast cancer with 10% TILs in April and May 2017, respectively. Neoadjuvant platinum- and taxane-based chemotherapy was administered concomitantly with 24 sessions of mEHT at the Cancer Center of Semmelweis University with the instrument EHY-2000 (Oncotherm Ltd., Budaörs, Hungary).

Figure 1; Histological appearance of the core biopsy displaying high grade invasive carcinoma /NOS/ (HE stains, 4x and 40× magnification).

Starting power [Watt]	Steps [Watt]	Time interval [Min]	Target power [Watt]	Treatment duration [Min]
60	5	6	105	60
60	5	6	75	60
60	5	6	70	60
30	5	6	35	60
30	5	6	50	60
30	5	6	50	60
30	5	6	40	60
30	5	6	80	60
30	5	6	80	60
30	5	6	80	60
30	5	6	80	60
30	5	6	80	60
30	5	6	80	60
30	5	6	80	60
30	5	6	80	60
30	5	6	55	60
30	5	6	75	60
40	5	6	80	60
40	5	6	80	60
60	5	6	65	60
60	5	6	65	60
60	5	6	80	60
50	5	6	60	60

Table 1; Applied mEHT treatment. mEHT treatment was performed with power starting at 30-60 Watt with 5-Watt steps every 6 minutes to 50-105 Watt. In two sessions lower maximum power was achieved as the patient's skin showed signs for light burning.

Figure 2. Pre and post treatment PET/CT scans. The primary tmor (**A**) and the lymph node metastasis (**B**) in April 2017 and the location of the regressed tumor in November 2017 (**C**).

Effect of the treatment was clearly demonstrated first in June 2017 with tumor size shrinkage of 11 mm and 16 mm measured with ultrasound and mammography, respectively. A second ultrasound examination in October 2017 showed 10 mm tumor and the following PET/CT identified 8×3 mm lesion. In November, same year, complete pathological response was achieved as no visible tumor was seen via mammography and after sector resection and axillary dissection as no tumor cells were detected by microscopic examination. Patient recovered well from chemotherapy side effects and operation..

Discussion: Complete pathological response was observed in a grade III, triple negative breast cancer after neoadjuvant platinum- and taxane-based chemotherapy and concomitant mEHT treatment. However, around one third of triple negative breast cancer patients' respond well to chemotherapy, the relatively high amount of tumor infiltrating lymphocytes at time of core biopsy and lack of specific immune stimulating treatment might be a sign of the determining contribution of mEHT to the pathological response. Moreover, this case suggests the immune-involvement in the molecular mechanism underlying the positive effect of mEHT treatment. Further research is needed to make effects and mechanisms of mEHT treatment deeper understood and its application more accepted.

Grant support: NVKP_16-1-2016-0042

Advanced cases

- The rest of patients were node positive and/or metastatic.
- The most common metastatic sites were
  - lymph nodes (9),
  - bone (5),
  - liver (4) and
  - lung (4) with
  - cutaneous involvement (2).
- The average time in treatment was 11.2 weeks (range: 2.4-23.2).
- One patient stopped at week 20 due to inflammed port and eight patients progressed in an average 9.7 weeks.

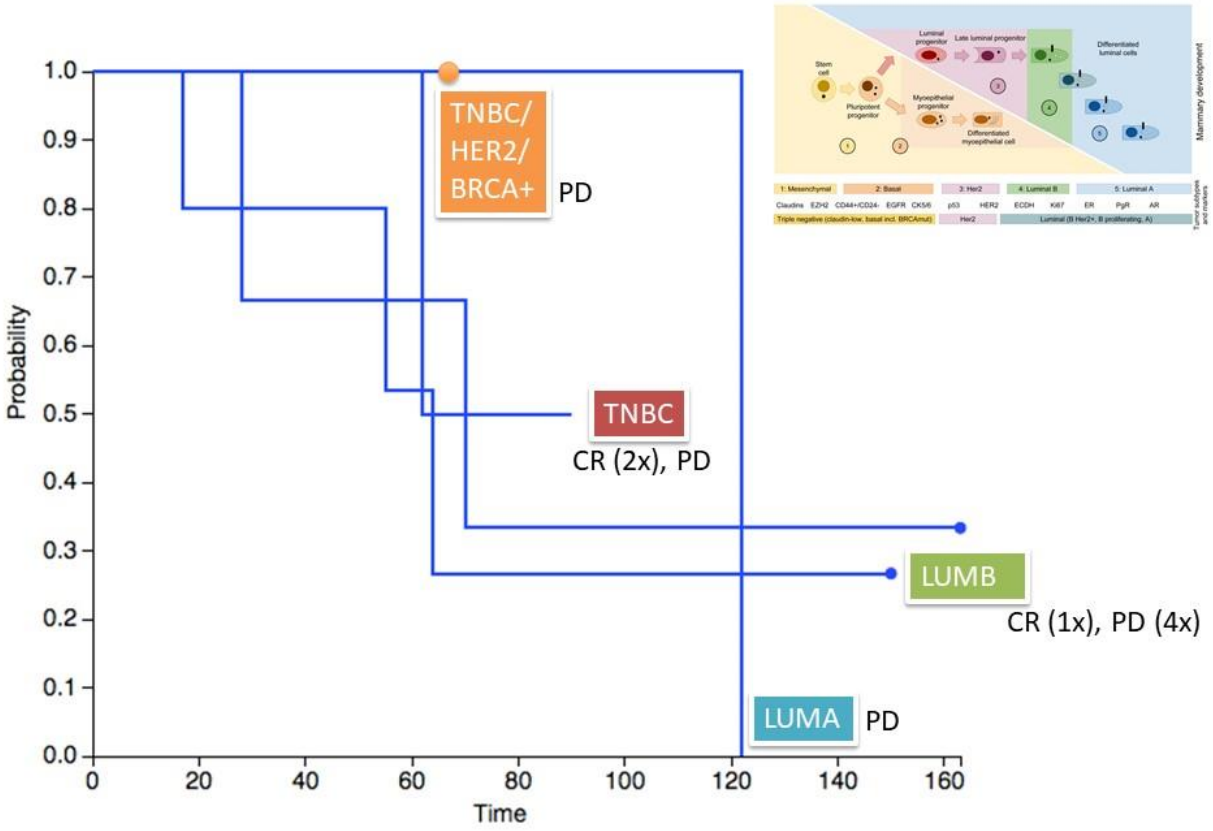

BRCA case (DOB: 1969)

- BRCA 1, exon 2, nucleotid 189, insertion 1A --» aminoacid 39 STOP codon, ONCOGENIC MUTATION
- Primary tumor (2014): ER-, PR, HER2-, p53-, Ki67 50% (pT2N1a)
  - TXT-CBP (6x), irradiation
- Supraclavicular metastasis (2015): ER-, PR-, HER2+ by FISH), p53-, KI67 80%
  - AC-trastuzumab (4x)
- Thoracal lesion (2016): ER-,PR-, HER2-, Ki67 60%
  - Lapatinib-capecitabine
- Mediastinal lesion (2017): PET/CT
  - Vinorelbine-mEHT
- Suprarenal and LN metastasis (2018): PET/CT
  - ADM-doxorubicin

Discussion

- Complementary mEHT treatment of breast cancer patients is feasible and easy to administer.
- Most **durable responses** were seen in skin metastases and/or bone, and decreasing time with lung and liver involvement.
- **Instinsic subtype** reflected by routine immunoprofiling is conserved in mEHY treated breast cancer.
- Most important favoring prognostic factors were lower stage and less number of metastases (oligometastatic status with maximally two distant metastatic sites).
- Younger age was a poor prognostic factor also accompanied with multiorgan metastases (3<).

Conclusion and directions

- Heterogeneity in the breast cancer population
- Survival improved greatly in the past 20 years
- Tumor biology is reflected
- Patients have more opportunities to get into clinical trials
- Heavily pretreated cases emerge
- Dismal prognosis when recruited to mEHY

surgery radiation chemotherapy hyperthermia

Grant support: NVKP_16-1-2016-0042