

Clinical Case Report

mEHT - Results on CA - Esthesioneuroblastoma- Brazilian Experience

Pontes, Shirley¹, Azevedo, Francisco²

¹Catholic University of Brasília – Brasil

²Instituto Medicina Biológica Brasília

E- mail: adm.imbiologica@gmail.com

E- mail: imbiologicabsb@gmail.com

Presented at 36th ICHS, Budapest, 2018

Cite this article as:

Pontes S. (2018): Clinical Case Report -mEHT - Results on CA - Esthesioneuroblastoma-
Brazilian Experience; *Oncothermia Journal* 24: 489-491

www.oncothermia-journal.com/journal/2018/Clinical_case_report.pdf

Clinical Case Report

mEHT - Results on CA - Esterioneuroblastoma - Brazilian Experience

Pontes, Shirley¹; Azevedo; Francisco H. F. MD²

¹Depto Gerontology on University Católica of Brasília

adm.imbiologica@gmail.com

²Instituto de Medicina Biológica

imbiologicabsb@gmail.com

Abstract

Cancer incidence in Brazil is as high as in developed countries. The Brazilian Unified Health System (SUS), which provides health care to the majority of the population, offers conventional oncology treatments such as chemotherapy, radiotherapy, hormonal suppressors and surgery. The possibility to offer modulated electro-hyperthermia (mEHT) is not yet being considered by the Government. There is, nevertheless, a growing number of cancer patients interested in the benefits of mEHT. Some of them, after being treated with traditional methods, see new hope in mEHT. Others see it as a complementary treatment. This report does not intend to provide scientific data, but rather a clinical contribution. Its aim is to present a case study, showing a brief patient history, the evolution of malignancy despite conventional treatments (chemotherapy, radiotherapy and immunotherapy) and the results with mEHT as well as support therapies. Conventional treatments were undertaken from 2015 to 2017, but were interrupted at the end of 2017 due to high toxicity. The treatment with mEHT and support therapies were provided from January to April 2018. The patient is male, white skin, 47 years old, diagnosed in 2014 by biopsy with Esthesioneuroblastoma (CID 10 C30). The clinical assessment at the beginning of the treatment with mEHT was: important edema on the left side of the face, severe convergent strabismus in the left eye, duplicated vision; patient reporting sedentary lifestyle, unrestricted feeding, insomnia, feeling depressive, discouraged, unable to work and drive, suffering sequel from previous and recent treatments, and weight loss of 20 kilos. PROTOCOL: mEHT -130 W/ 60min 3 X week total of 36 sessions; no chemotherapy or radiotherapy; oxygen therapy by Manfred Von Ardenne, galvanic micro-current, pulsed magnetotherapy field, Rife frequency therapy (36 session - 20 min), endovenous supplementation of minerals, vitamins, amino acids (500 ml X 12 session) and curcumin supplementation (SC 24 X 200 mcg, 2 ml), ozonotherapy rectal twice a week, reduced intake of simple carbohydrates, Joanna Budwig diet, homeopathic support, and "a more healthy lifestyle". The RESULTS on PETscan dated of April 2018 and the oncological evaluation confirms the total remission of the Esthesioneuroblastoma and cervical lymph nodes, total remission of the facial edema, and 90% strabismus reduction. The clinical impressions show significant improvement of energy and quality of life, and great improvement of vision. A slight strabismus still remains to be analyzed by the ophthalmologist. The patient continues with a low carb diet. The patient is able to safely drive and returned to normal work activities. Suggested oncological follow-up every six months.

Clinical Case Report

mEHT - Results on CA - Esthesioneuroblastoma- Brazilian Experience

Pontes, Shirley. Gerontologist, Catholic University of Brasília – Brasil
 Azevedo, Francisco. MD, Instituto Medicina Biológica Brasília - Brasil

email: adm.imbiologica@gmail.com
 email: imbiologicabsb@gmail.com



INTRODUCTION

Cancer incidence in Brazil is as high as in developed countries. The Brazilian Unified Health System (SUS), which provides health care to the majority of the population, offers conventional oncology treatments such as chemotherapy, radiotherapy, hormonal suppressors and surgery. The possibility to offer modulated electro-hyperthermia (mEHT) is not yet being considered by the Government. There is, nevertheless, a growing number of cancer patients interested in the benefits of mEHT. Some of them, after being treated with traditional methods, see new hope in mEHT. Others see it as a complementary treatment. This report does not intend to provide scientific data, but rather a clinical contribution.

AIM

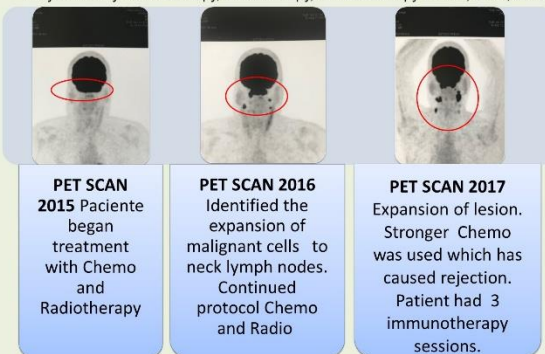
Its aim is to present a case study, showing a brief patient history, the evolution of malignancy despite conventional treatments (chemotherapy, radiotherapy and immunotherapy) and the results with mEHT as well as support therapies.

DEVELOPMENT

The patient is male, white skin, 47 years old, diagnosed in 2014 by biopsy with Esthesioneuroblastoma (CID 10 C30). Conventional treatments were undertaken from 2015 to 2017, but were interrupted at the end of 2017 due to high toxicity. The treatment with mEHT and support therapies were provided from January to April/2018.

The clinical assessment at the beginning of the treatment with mEHT was: Important edema on the left side of the face, severe convergent strabismus in the left eye, duplicated vision; patient reporting sedentary lifestyle, unrestricted feeding, insomnia, feeling depressive, discouraged, unable to work and drive, suffering sequel from previous and recent treatments, and weight loss of 20 kg.

Polytreated by Chemotherapy, Radiotherapy, Immunotherapy - 2015, 2016, 2017.



PET SCAN 2015
 Paciente began treatment with Chemo and Radiotherapy

PET SCAN 2016
 Identified the expansion of malignant cells to neck lymph nodes. Continued protocol Chemo and Radio

PET SCAN 2017
 Expansion of lesion. Stronger Chemo was used which has caused rejection. Patient had 3 immunotherapy sessions.

The results show recurrence and increased lesion. In 2017 the medical team appealed to Immunotherapy as the last possibility- on the 3rd session they chose to discontinue due to prohibitive toxicity.

Clinical impression: The patient had important edema on the left side of the face, severe convergent strabismus in the left eye, vision duplicated, patient confirms insomnia, sedentary, unrestricted feeding. Depressive, discouraged, unable to work and drive, suffering sequel from previous treatments. Weight loss of 20 kilos.

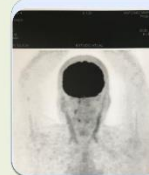
2018 - mEHT - Protocol used from January to April 2018.

Protocol description: Follows the basic propositions of mEHT: Using the medium bolus electrode size applied on the face. 12 sessions/month. No chemotherapy or radiotherapy was used.

- mEHT 3 X week 130 W/ 60min. Total 36 session.
- Reduced intake of simple carbohydrates, Dra. Joana Budwig diet, Homeopatic support, and "Health life style" suggested.
- As complementary therapy used Oxygen therapy + galvanic micro current + magneto therapy + Rife frequency (36 session - 20 min), endovenous supplementation of minerals, vitamins, amino acids (500 ml X 12 session) and curcumin (SC 24 X 200 mcg, 2 ml), Ozonioterapia Retal 2 X week.

RESULTS

From Jan to April/18 the patient has done 36 session of mEHT protocol+ support therapies. The patient shows clinical aspects improvements and 100% reduction of facial edema, 80% reduction of strabism. On PETscan May /18 – compared to previous images, confirm great remission:



"Resolution of hypermetabolism on nasopharyngeal lesion in the inferior turbinate medial wall of the left maxillary sinus and bilateral cervical lymphonodes." PETscan May2018

FINAL CONSIDERATIONS

From Jan to April 2018 with the mEHT protocol + support therapies, notice the total reduction of facial edema and according to images + reports, the oncological evaluation confirms an unequivocal remission of the CA – Esthesioneuroblastoma and cervical lymphonodes.

The clinical assessments show improvement of energy and quality of life, great improvement of vision. Still remains a slight strabismus, and the suggestion of the ophthalmologist is to perform a surgical correction in near future.

Since then, the patient continues with low carb diet, supplementation. He returns to normal work activities. And we suggested an oncological follow-up every six months.

Submitted to
36th ICHS Conference
 Budapest Hungary - Sept/2018