Possible potentiation of the abscopal effect of ionising radiation by modulated electro-hyperthermia in locally advanced cervical cancer patients

Carrie Anne Minnaar[1], Jeffrey A. Kotzen[2], Ans Baeyens[3]
[1]University of the Witwatersrand, Radiation Sciences: Radiobiology, Johannesburg, South Africa.
[2] Wits Donald Gordon Medical Centre, Radiation Oncology, Johannesburg, South Africa.
[3] Ghent University, Basic Medical Sciences, Ghent, Belgium

Presented at 36th ICHS, Budapest, 2018

Cite this article as:
Minnaar CA. (2018): Possible potentiation of the abscopal effect of ionising radiation by modulated electro-hyperthermia in locally advanced cervical cancer patients; Oncothermia Journal 24:122-132
www.oncothermia-journal.com/journal/2018/Possible_potentiation_of_the_abscopal_effect.pdf

Possible potentiation of the abscopal effect of ionising radiation by modulated electro-hyperthermia in locally advanced cervical cancer patients

Carrie Anne Minnaar[1], Jeffrey A. Kotzen[2], Ans Baeyens[3]
[1]University of the Witwatersrand, Johannesburg, South Africa;
[2]Wits Donald Gordon Medical Centre, Johannesburg, South Africa; 3 Ghent University, Ghent, Belgium

Introduction

Literature has shown that the local application of ionising radiation is able to induce a response at distant sites of disease. This effect, known as the abscopal effect, is generally accepted to be mediated by the triggering of an immune response by ionising radiation. The application of hyperthermia has also been suggested to enhance the abscopal effect. Our ongoing phase III randomised clinical study investigates the effects of the addition of modulated electro-hyperthermia (mEHT) on chemoradiotherapy in locally advanced cervical patients. We assess the response of the tumour and lymph nodes inside and outside of the radiation treatment field based on PET/CT images and report on the potential abscopal effect mediated by mEHT.

Methods

Participants enrolled in the study had FIGO stage IIb (distal parametrium involvement) to IIIb (bilateral hydronephrosis excluded) cervical cancer. HIV positive participants were included if their CD4 count was >200cells/mL or they had been on antiretroviral therapy for more than 6 months. Participants were randomised into a mEHT arm or a control arm. All participants were prescribed 50Gy external beam radiation to the pelvis in 25 fractions, plus 3 fractions of 8Gy High Dose Rate (HDR) Brachytherapy. Participants in the mEHT arm were prescribed 2 mEHT treatments per week during external beam radiation using modulated 13.56MHz capacitive heating (55 minutes; 130W). 155 pre-treatment and 155 post-treatment 18F-FDG PET/CT scans were analysed. Each region (head and neck; thorax; abdomen; pelvis) was scored according to the nodes visualised on 18F-FDG PET/CT: no change in the number of visualised nodes; resolution of all nodes; new nodes; no nodes in either pre- or post-treatment scans. Tumour response was reported based on PERCIST version 1.0 criteria.

Results

56% and 62% of the participants in the mEHT and control arm respectively had nodes with an 18F-FDG Standard Uptake Value of more than 2.5 visualised on PET/CT before treatment. A complete metabolic response of the tumour was significantly higher in the participants in the mEHT group than in the participants in the control group (58% versus 37% respectively). The number of participants with a complete metabolic response of the tumour and extra-pelvic nodes was also significantly higher in the mEHT group versus in the control group (27.7% vs 6.8%; Chi2: p=0.009).

Conclusion

In our study, the addition of mEHT may be contributing to an enhanced abscopal effect with a significantly higher increase in the complete metabolic response of nodal disease outside of the treated area observed in the mEHT group.

Possible potentiation of the abscopal effect of ionising radiation by modulated electro-hyperthermia in locally advanced cervical cancer patients

C.A. Minnaar[1]; J.A. Kotzen[2]; A. Baeyens[3]

1. University of the Witwatersrand, Radiation Sciences: Radiobiology, Johannesburg, South Africa.
2. Wits Donald Gordon Medical Centre, Radiation Oncology, Johannesburg, South Africa.
3. Ghent University, Basic Medical Sciences, Ghent, Belgium

Disclosures

The authors are not aware of any circumstances which may lead to a conflict of interest.

Introduction

IR can trigger regression of metastases outside of the treated radiation field.

Abscopal effect

- Believed to be due to a systemic immune reaction towards targeted malignant cells elicited by IR.
- *IR is able to trigger the immune response towards metastatic disease.*

Only a handful of cases are reported annually in the literature.

Introduction

First described in 1979 by Slone *et al.*, who showed that the degree of integrity of the immune system had an effect on the radiosensitivity of the tumour.

In murine fibrosarcoma models, the RT dose needed to control tumour growth in T-cell competent mice was compared to the dose needed to control the tumour growth in T cell-deficient mice.

The average RT dose required was lower and the likelihood of developing metastases was lower in T cell-competent mice.

Introduction

Systemic immunotherapies added to RT =

-Increase in the number of abscopal effects

-Increased interest in the field

The abscopal effect has also been described after the application of hyperthermia combined with RT

HT may therefore enhance the abscopal effect…

Objective

Ongoing phase III, randomised trial in South Africa investigating the effects of the addition of modulated electro-hyperthermia (mEHT) on chemoradiotherapy in locally advanced cervical patients - with particular interest in HIV-positive patients.

We assess the response of the tumour and lymph nodes inside and outside of the radiation treatment field on PET/CT images and report on the potential abscopal effect mediated by mEHT.

Methodology

- FIGO stage IIb to IIIb cervical cancer
- HIV-positive and -negative
- CD4 count >200cells/mL OR on ARVs> 6 months
- Bilateral hydronephrosis excluded

Randomised: mEHT /Control (stratum: HIV; Age; Stage)

Treatment:
50Gy EBRT (25 fractions) + 3 fractions of 8Gy HDR Brachytherapy
Cisplatin (planned 2 doses of 80mg/m2)

mEHT group received 2 mEHT / week (55 minutes; 130W)

LDC measured at 6 months post treatment using ^{18}F-FDG PET/CT images.

Methodology

155 pre-treatment and matching post-treatment ^{18}F-FDG PET/CT scans were analysed;

Pre-treatment scans with extra-pelvic nodes were compared to post treatment scans of the same participants.

Each region (head and neck; thorax; abdomen; pelvis) was scored according to the nodes visualised on ^{18}F-FDG PET/CT:

1. no change in the number of visualised nodes;
2. resolution of all nodes;
3. new nodes;
4. no nodes in either pre- or post-treatment scans.

Tumour response was reported based on PERCIST version 1.0 criteria.

Results

54 Participants from each treatment group had nodes visualised on the pre-treatment ^{18}F-FDG PET/CT scans outside the radiation field.

Of which: 26 of the mEHT Group participants (25%) and 29 of the Control Group participants (28%) had para-aortic nodes.

Results

- Complete Metabolic Response of the Tumour:
  58% (mEHT) versus 37% (control)
  Pearson's Chi2: p=0.006.
- Complete Metabolic Response of the Tumour and extra-pelvic nodes:
  28% (mEHT) versus 7% (control)
  Pearson's Chi2: p=0.009.
- Complete Metabolic Response of the Tumour, pelvic and extra-pelvic nodes:
  24.1% (mEHT) versus 5.6% (control)
  Pearson's Chi2: p=0.007.

Results

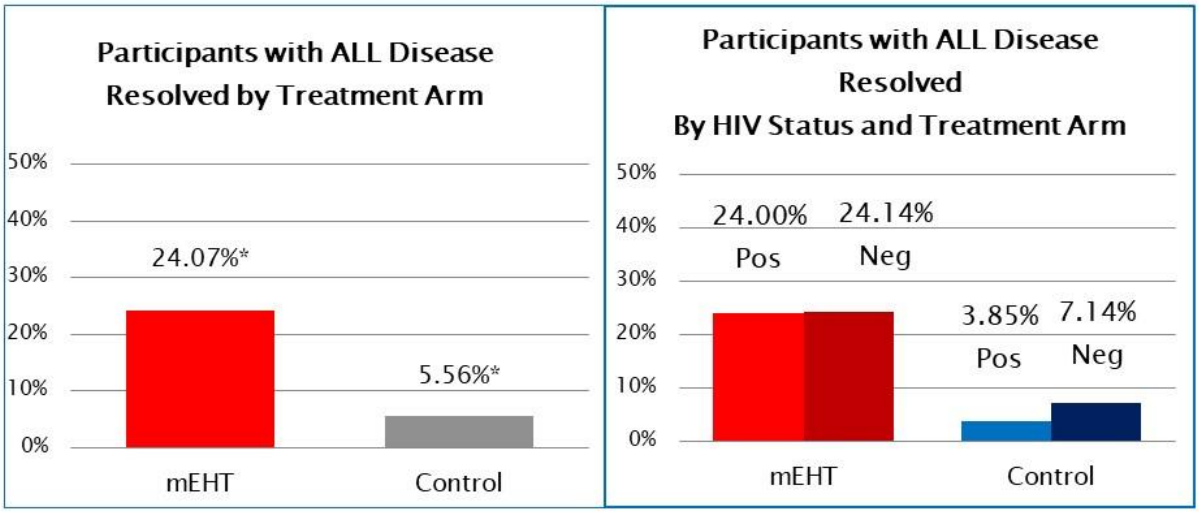

Pearson's Chi2: p=0.007

Results

One Participant had neck and thorax nodes, bone, and lung metastases on pre-treatment scan.

- HIV negative
- Stage IIIB
- Age 34 years
- 2 Chemotherapy doses

Post treatment scan showed complete response of all disease

Results

Characteristics of abscopal participants

	mEHT		Control	
n	*13*		*3*	
HIV Positive	*6*	46%	*1*	33%
0 Cisplatin	*1*	8%	*1*	33%
1 Cisplatin	*4*	31%	*0*	0%
2 Cisplatin	*8*	62%	*2*	67%
Stage IIB	*6*	46%	*2*	67%
Stage IIIA	*0*	0%	*0*	0%
Stage IIIB	*7*	54%	*1*	33%
Min Age	30		28	
Max Age	64		66	
Mean Age	50.4		53.0	

Conclusion

In our study, the addition of mEHT may be contributing to an enhanced abscopal effect with a significantly higher increase in the complete metabolic response of nodal disease outside of the treated area observed in the mEHT group.

A detailed analysis of the results is in process

Discussion

1. Resolution of extra-pelvic nodal disease + pelvic disease= Abscopal effect

2. Significantly higher rate in the mEHT group: Abscopal effect potentiated by the addition of mEHT?

3. The addition of immunotherapy drugs to mEHT + RT may potentiate systemic anti-tumour effects of IR

4. Future Research:
   a) Investigations into biomarkers predicting/ indicating the presence of the abscopal effect
   b) Studies investigating this combination of treatment are warranted.

Acknowledgements

- Trial funded by the South African National Research Foundation (NRF)
- Device supplied by Oncotherm GmBH
- 18F-FDG isotopes supplied at research costs by NTP (Pty)Ltd

Thank you to my colleagues, supervisors and mentors, and to all of the participants without whom this trial would not have been be possible.

Thank You

of 18

17

References

- Slone HB, Peters LJ, Milas L. Effect of Host Immune Capability on Radiocurability and Subsequent Transplantability of a Murine Fibrosarcoma2. J Natl Cancer Inst. 1979;63(5):1229-35.
- Brix N, Tiefenthaller A, Anders H, Belka C, Lauber K. Abscopal, immunological effects of radiotherapy: Narrowing the gap between clinical and preclinical experiences. Immunol Rev. 2017;280(1):249-79.
- Datta NR, Ordóñez SG, Gaipl US, Paulides MM, Crezee H, Gellermann J, et al. Local hyperthermia combined with radiotherapy and-/or chemotherapy: Recent advances and promises for the future. Cancer Treat Rev. 2015;41(9):742-53.
- Ngwa, W. *et al.* (2018) 'Using immunotherapy to boost the abscopal effect', *Nature Reviews Cancer*. Nature Publishing Group, a division of Macmillan Publishers Limited. All Rights Reserved., 18(5), pp. 313-322. doi: 10.1038/nrc.2018.6.
- Okuma K, Yamashita H, Niibe Y, Hayakawa K, Nakagawa K. Abscopal effect of radiation on lung metastases of hepatocellular carcinoma : a case report. *J Med Case Rep*. 2011;5(1):111. doi:10.1186/1752-1947-5-111
- Reynders, K. *et al.* (2015) 'The abscopal effect of local radiotherapy: Using immunotherapy to make a rare event clinically relevant', *Cancer Treatment Reviews*. Elsevier Ltd, 41(6), pp. 503-510. doi: 10.1016/j.ctrv.2015.03.011.
- 14. Cotter S, Dunn G, Collins K, et al Abscopal effect in a patient with metastatic merkel cell carcinoma following radiation therapy: Potential role of induced antitumor immunity. *Arch Dermatol*. 2011;147(7):870-872.
- Takaya, M. *et al.* (2007) 'Abscopal Effect of Radiation on Toruliform Para-aortic Lymph Node Metastases of Advanced Uterine Cervical Carcinoma - A Case Report', 504, pp. 499-503.
- Tubin, S. *et al.* (2012) 'A Case Report on Metastatic Thyroid Carcinoma : Radiation-induced Bystander or Abscopal Effect ?', *Journal of Cancer Science and Therapy*, 4(12), pp. 408-411. doi: 10.4172 5956.

18