

How to set up an individual program of hyperthermia and conventional treatment in heavily pretreated cancer patients

Alexander Herzog

Fachklinik Dr. Herzog, Bad Salzhausen, Germany

Presented at the 37th ICHS, Thessaloniki

Cite this article as:

Herzog A. (2019): How to set up an individual program of hyperthermia and conventional treatment in heavily pretreated cancer patients, Oncothermia Journal 27: 188-195
www.oncotherm.com/sites/oncotherm/files/2019-10/How_to_set_up_an_individual_program.pdf

Hyperthermia is not sufficient as sole treatment. Even though there are experimental studies on cancer cells and in animals showing that hyperthermia may kill cancer cells, in patients up to now the results are not satisfactory.

But hyperthermia may serve as an important tool to improve the efficacy of conventional treatments like chemotherapy or radiation. This has been shown in numerous studies in particular in advanced, recurrent or metastatic disease. But to achieve good results it is not enough to just perform hyperthermia. A skilful setting of hyperthermia and conventional treatments is crucial.

There are not only different types of hyperthermia (superficial, deep-regional, whole-body hyperthermia), there are also several different drugs of chemotherapy and different techniques of radiation which must be put together in a correct order to achieve best possible success.

For first- or second-line treatment of cancer there are in general guidelines clearly showing possible success rates of certain treatments whereas in heavily pre-treated patients there are no guidelines anymore. So individual treatment concepts have to be set up.

In three exemplary patients (pancreatic cancer with peritoneal carcinosis, recurrent synovial sarcoma and non-small-cell lung cancer) treatment strategies are explained and the outcome discussed.

Patient 1: Diagnosis: Pancreatic cancer with peritoneal metastases

Oncological history:

- 11/15 Advanced cancer of pancreatic tail. Distal pancreatectomy, splenectomy, left colectomy.
- 01/16 FOLFIRINOX 12 cycles.
- 03/17 Carcinosis of gall bladder. Cholecystectomy. Pembrolizumab for 10 cycles. Progressive peritoneal carcinosis.
- 10/17 T-cell immunotherapy, PD.
- 12/17 Ileus and jaundice. Removal of parts of small intestine removed. Ileostomy. Bile duct metal stent
- 02/18 Subileus, nasogastric tube, parenteral nutrition (Image 1)

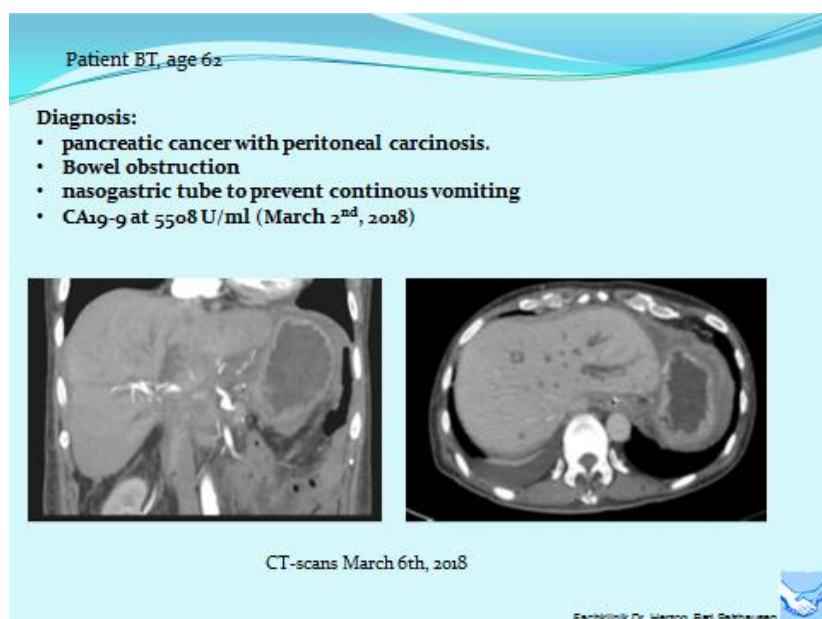


Image 1

Problem: The patient was heavily pre-treated with chemotherapy (Folfinirox), immunotherapies and several surgeries. He came to us in a terminal situation, was not able to eat anymore and had a nasogastric tube because of continuous vomiting. The tumor marker CA19-9 was >5.000. The patient was extremely weak and in pain. No treatment options and no likelihood of response to chemotherapy anymore. (Johns Hopkins center, USA) To decide about a treatment in such a difficult situation it is necessary to consider all relevant factors. (Image 3)

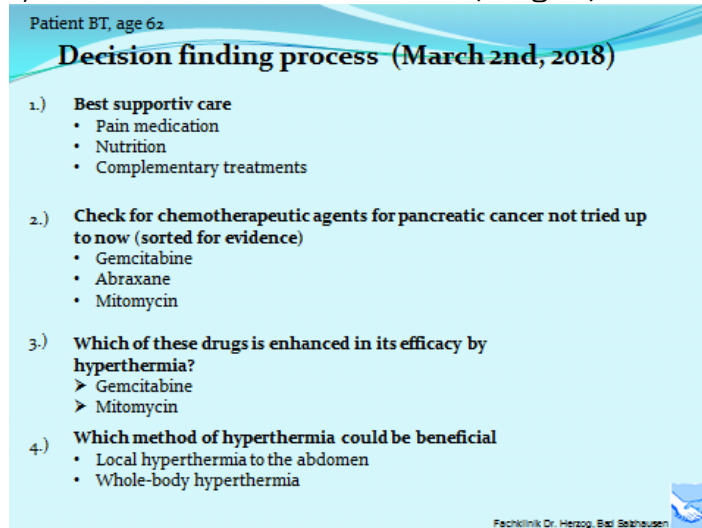


Image 2

Solution:
 03/18 Local and whole body hyperthermia (Oncotherm EHY 2000, Iratherm 2000) In combination with Gemcitabine. Parenteral nutrition and complementary treatments.

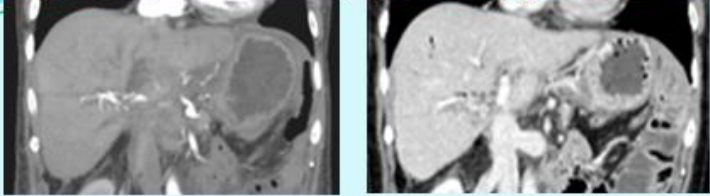
Result: Decrease of tumor markers. Normal food uptake and bowl function, good quality of life again.

10/18 Maintenance therapy with Capecitabine and hyperthermia.
 04/19 Cholangitis and stenosis of bile duct stent. Placement of 2 plastic stents into the metal stent. Continuation of Capecitabine and hyperthermia.
 06/19 Lasting PR, Ca19-9 at 73,6ng/ml, good quality of life.

Comment: Given the situation of this patient in the beginning a survival beyond a few weeks was not likely. Now 1 1/2 years after first admission the patient is still alive and in a good condition. Only the combined treatment adding hyperthermia to chemotherapy can explain this outcome. After Gemcitabine alone in his condition such a result never would have been expected. (Image 3)

Patient BT, age 62 Diagnosis: pancreatic cancer with peritoneal carcinosis

03/18 04/19



- ❖ At start of treatment no promising options
- ❖ Expected success of Gemcitabine alone in best case szenario: few months
- ❖ Hyperthermia seems to have been the crucial factor of success
- ❖ Possible benefit of hyperthermia plus Gemcitabine in pancreatic cancer is supported by studies

Fachklinik Dr. Herzog, Bad Bollhausen

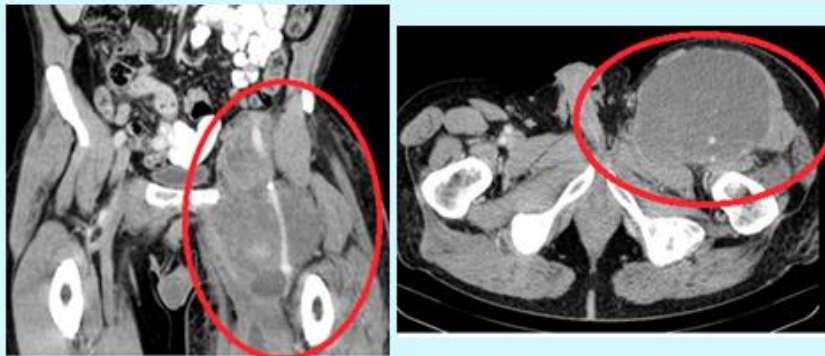Image 3

Patient 2: Diagnosis: Synovial sarcoma of left knee

Oncological history:

- 01/16 Lump at left knee, at biopsy synovial sarcoma
- 03/16 Resection, stage pT2R0
- 04/16 Radiation of the distal right femur
- 12/16 Local recurrence above the field of radiation
- 01/17 Resection of recurrence, Radiatio and brachytherapy
- 06/17 Grossly swollen left leg, thrombosis of the vena femoralis caused by large tumour metastases in the left groin.
- 08/17 Chemo-immunotherapy with Doxorubicin and Olaratumab, PD
- 10/17 Carboplatin and Gemcitabine, PD
- 12/17 Pazopanib, PD
- 02/18 One cycle of Ifosfamide high dose, not tolerated (encepalopathy). Progression of the disease resulting in a tumour of more than 11 cm diameter in the left groin reaching into the pelvis, compressing bladder and ureter and growing around the blood vessels and nerves of the left leg. 3 more large masses along and around the arteria femoralis down the left thigh, the lowest mass a few centimeters above the inner left knee. (Image 4)

Patient KB, age 63 years, Diagnosis: recurrent synovial sarcoma left knee with metastases to the lymph nodes of thigh and left pelvis



25.01.2018

Image 4

Fachklinik Dr. Herzog, Bad Salzhausen

Problem: Metastatic sarcoma of the left knee spreading into the lymphatic tissues along the left thigh up to the pelvis. Progression after 3 lines of chemotherapy and immunotherapy. The last chemotherapy with Ifosfamid in high dose he almost had not survived. No other treatment options now than left hemipelvectomy and amputation of the left leg. (Image 5)

Decision finding process (February 2018)

- 1.) **Best supportiv care**
 - Pain management
 - Lymphatic massage
 - physiotherapy to maintain mobility
- 2.) **Check for chemotherapeutic agents not tried up to now**
 - All possible options used
 - But Ifosfamide only short time, just not tolerated in high dose as monotherapy ($4g/m^2 \times 3days$)
 - Ifosfamide is enhanced by hyperthermia
- 3.) **Which method of hyperthermia could be beneficial**
 - Local hyperthermia in several alternating fields

Image 5

Fachklinik Dr. Herzog, Bad Salzhausen

Solution: Continuation of Ifosfamide but in lower doses ($2,2 g/ m^2/ 24 hrs \times 3 days$) combined with local hyperthermia (Oncotherm EHY 2000) to the metastatic sites at pelvis and left thigh.

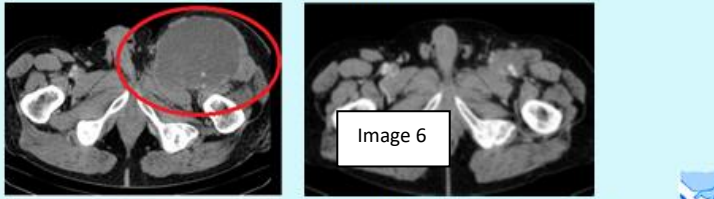
Result: Very good partial remission. The patient was free of pain, could walk again without crutches, the swelling of the leg had come down. (Image 6)

Treatment plan:

Chemotherapy → Ifosfamide in reduced dose (2,2g/m² x 3days, 4 cycles)
 Hyperthermia → several sessions of local hyperthermia to the different sites from pelvis to knee (EHY 2000, Oncotherm)

Goal: Reduction of tumors to prevent hemipelvectomy and to allow a less traumatic and debilitating leg amputation

Result (06/18): very good partial remission
 regain of mobility, no pain anymore
 patient operable now for limb saving surgery
 (University hospital Heidelberg)



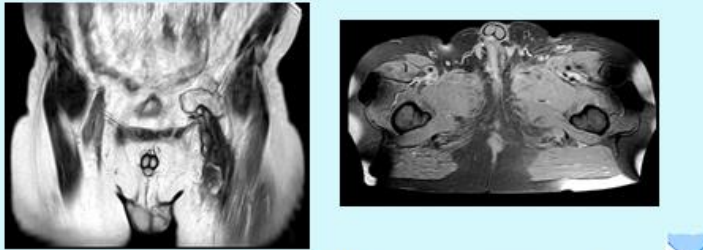
25.01.2018 15.06.2018 Fachklinik Dr. Herzog, Bad Seibershausen

Comment: Because of the good response amputation was not necessary anymore. Limb saving treatment was now considered. This result can only be explained by the additional treatment with hyperthermia.

But the patient didn't want to have surgery because of possible damage. (Image 7)

Further development

- Patient refused surgery, wanted to keep his leg
- Hyperthermia continued as sole therapy
- 11/18 PD again, but still no distant metastases
- 01/19 Proton therapy plus local hyperthermia, PR
- 09/19 SD, patient active, exercising, walking on both legs, good quality of life



27.06.2019 Fachklinik Dr. Herzog, Bad Seibershausen

Patient 3: Diagnosis: NSCL (adenocarcinoma) with metastases to the brain (EGFR pos.)

Oncological history:

- 01/11 Adenocarcinoma of the left lung with brain metastases (T3, M1), surgery of the brain metastases, chemotherapy with Carboplatin and Vinorelbine, radiation of the lung tumour and the brain.
- 07/11 Progression of the brain metastases, treatment with Gammaknife.
- 10/11 Progression in the lung, Pemetrexed
- 02/12 Progression in the brain and the lung, treatment with Gammaknife for the brain. Treatment with Tarceva for the lungs, progressive disease. (Image 8)

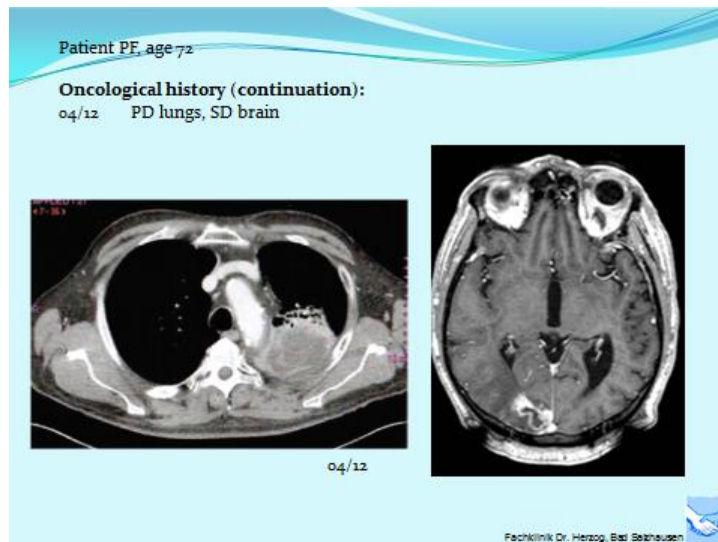


Image 8

Problem: Progressive disease after multiple chemotherapies and targeted therapy. He suffered from cough and chest pain. No treatment options anymore, the tumor was considered as resistant to further chemotherapy. (Image 9)

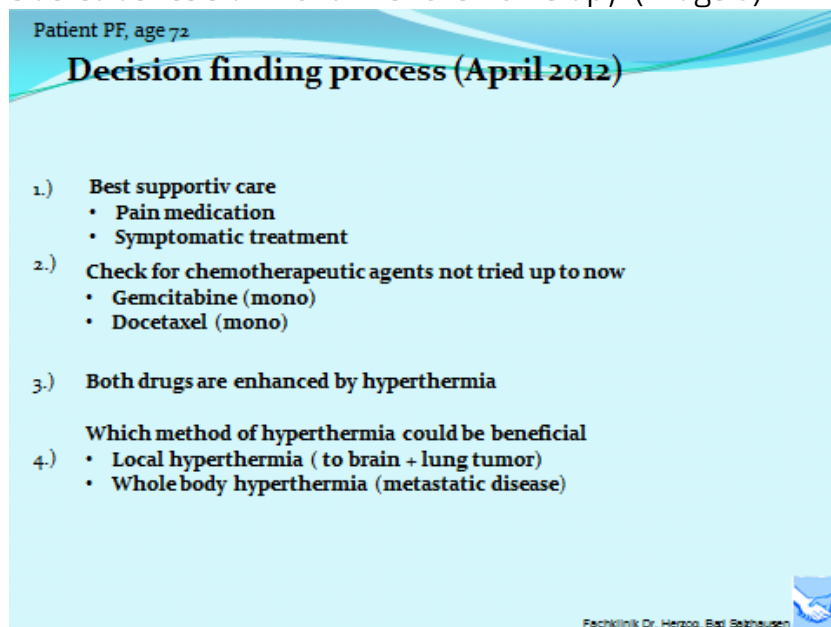


Image 9

Solution: Whole body and local hyperthermia in combination with Taxotere in moderate doses.

Result: Partial remission of the pulmonary disease, no new activity in the brain

Further development:

03/15 Stereotactic radiation of the remaining lung tumor

Since 10/15 normalization of tumor markers, no evidence of active disease. (Image 10)

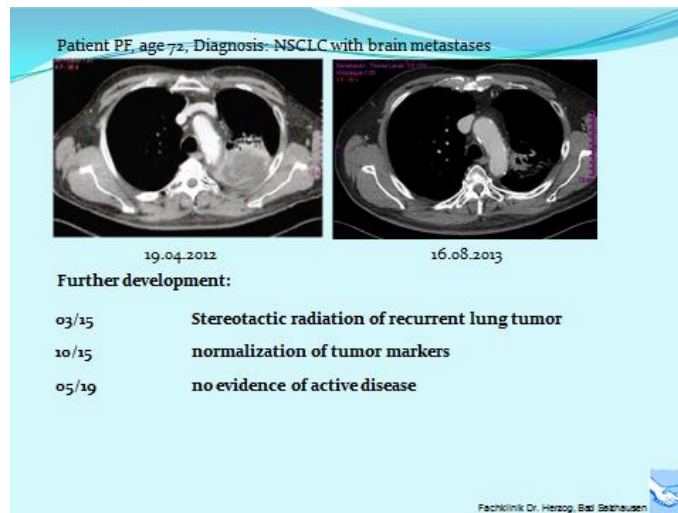


Image10

Comment: In this patient the likelihood of response to further chemotherapy was little and if at all only for a short time. Hyperthermia in this case very likely helped to overcome resistance and enabled long term survival. The patient has now been free of disease for more than 4 years (since March 2015), he is in a good quality of life. He comes every 6 months for check-up.

Conclusion

Even in heavily pre-treated patients there is a chance to achieve a good and long-lasting treatment success. Hyperthermia in these cases seems to be the crucial tool. The setting in each situation has to be a specific combination with adapted programs of conventional treatments like chemotherapy and radiation.