

mEHT - Results on CA - Esterioneuroblastoma - Brazilian Experience

Shirley Pontes¹, Francisco Azevedo²

¹Gerontologist, Catholic University of Brasília

² Instituto Medicina Biológica Brasília - Brasil

¹E-mail: adm.imbiologica@gmail.com

²E-mail: imbiologicabsb@gmail.com

Presented at the 37th ICHS, Thessaloniki

Cite this article as:

Pontes S., Azevedo F. (2019): Effectiveness Clinical Case Report
mEHT - Results on CA - Esterioneuroblastoma - Brazilian Experience, *Oncothermia Journal* 27: 76- 87
www.oncotherm.com/sites/oncotherm/files/2019-10/mEHT_Results_on_CA.pdf

Cancer incidence in Brazil is as high as in developed countries. The Brazilian Unified Health System (SUS), which provides health care to the majority of the population, offers conventional oncology treatments such as chemotherapy, radiotherapy, hormonal suppressors and surgery. The possibility to offer modulated electro-hyperthermia (mEHT) is not yet being considered by the Government. There is, nevertheless, a growing number of cancer patients interested in the benefits of mEHT. Some of them, after being treated with traditional methods, see new hope in mEHT. Others see it as a complementary treatment. This report does not intend to provide scientific data, but rather a clinical contribution.

Aim

Our aim is to present a case study, showing a brief patient history, the evolution of malignancy despite conventional treatments (chemotherapy, radiotherapy and immunotherapy) and the results with mEHT as well as support therapies. Conventional treatments were undertaken from 2015 to 2017 but were interrupted at the end of 2017 due to high toxicity. The treatment with mEHT and support therapies were provided from January to April/2018.

Development

The patient is a white skin, 47 years old male, diagnosed in 2014 by biopsy with Esthesioneuroblastoma (CID 10 C30). The clinical assessment at the beginning of the treatment with mEHT was: important edema on the left side of the face, severe convergent strabismus in the left eye, duplicated vision; patient reporting sedentary lifestyle, unrestricted feeding, insomnia, feeling depressive, discouraged, unable to work and drive, suffering sequel from previous and recent treatments, and weight loss of 20 kilos.

Protocol

mEHT -130 W/ 60min 3 times a week, a total of 36 sessions; no chemotherapy or radiotherapy; oxygen therapy by Manfred Von Ardenne, galvanic micro-current, pulsed magnetotherapy field, Rife frequency therapy (36 session - 20 min), endovenous supplementation of minerals, vitamins, amino acids (500 ml X 12 session) and curcumin supplementation (SC 24 X 200 mcg, 2 ml), ozone therapy rectal 2 X week, reduced intake of simple carbohydrates, Joanna Budwig diet, homeopathic support, and "a more healthy lifestyle".
RESULTS: on Pet scan dated April/2018 and the oncological evaluation confirms the total remission of the Esthesioneuroblastoma and cervical lymph nodes, total remission of the facial edema, and 90% strabism recuction. The clinical impressions show significant improvement of energy and quality of life, and great improvement of vision. Still remains a slight strabismus, to be analyzed by the ophthalmologist. The patient continues with a low carb diet. He is able to drive safely and returned to normal work activities. Suggested oncological follow-up every six months.



37th Conference of the International Clinical Hyperthermia Society
September 19-21, 2019

mEHT- Clinical Case Report Results on CA – EsterioNeuroblastoma - Brazilian Experience

MD - Dr. Francisco Humberto F. Azevedo
MSC Shirley Pontes
Brasilia , BRASIL
20/ Sept/ 2019



mEHT- in Brazil Cancer Treatment



MD Dr. Francisco Humberto F. Azevedo

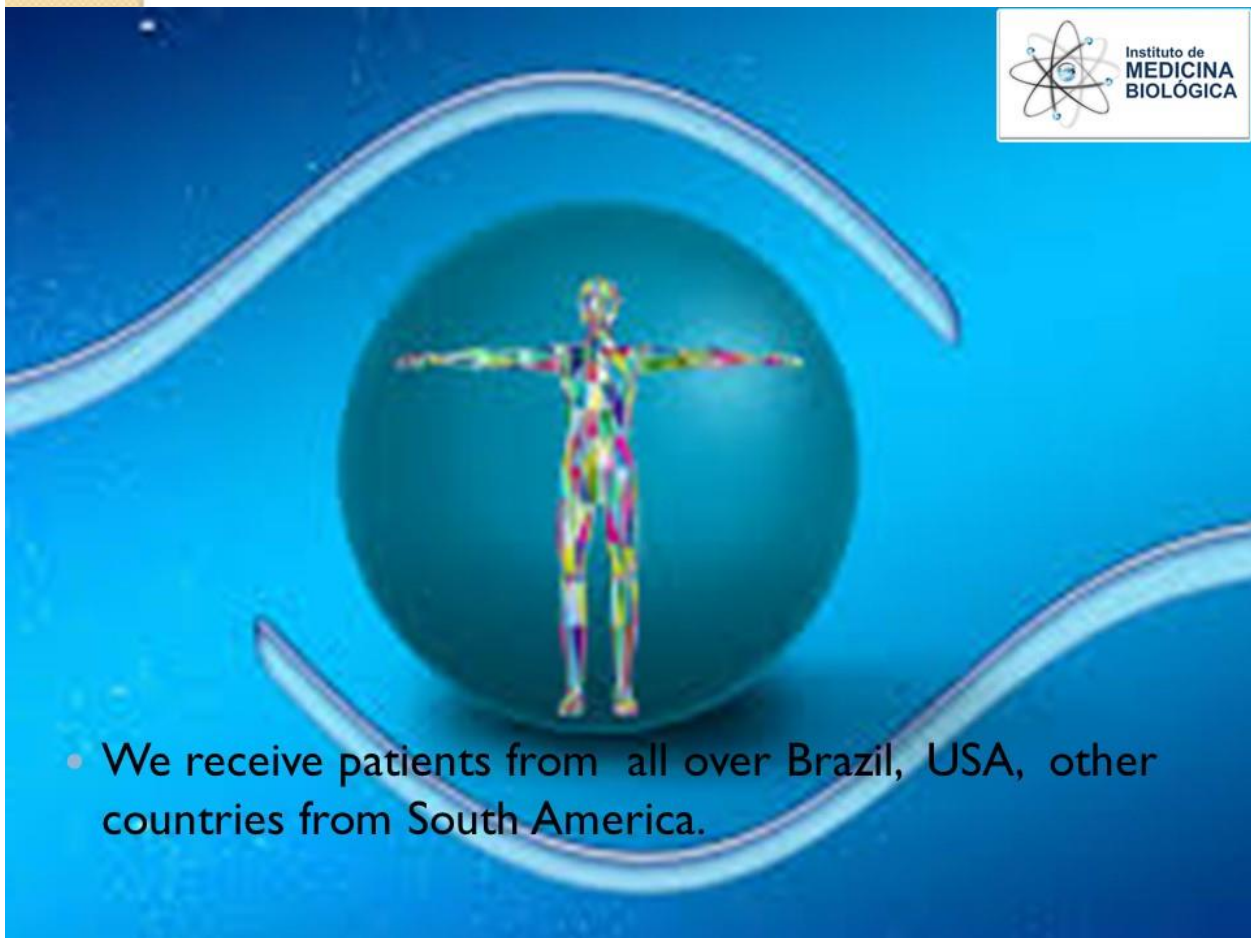
43 year MD (Surgeon + Homeopathic +
Nutrologist) since the last 20 years he is using
Integrative therapies on treatments

Shirley Pontes – Gerontologist

Master in Prostate Cancer toxicity of RT, QT,
Hormone therapy and PR radical
Fitoterapist + Integrative therapies

mEHT against Cancer in Brazil

- First EHY2000 imported in Brazil - 2012;
- Treatments since 2013;
- mEHT is considered as a complementary treatment;
- There is no legislation about it.
- Legislation: Still in process of Register
- We are against the “Main Stream power”
- FDA – USA inspires legislation to ANVISA- Brazilian Regulation Agency



The Cancer in Brazil

Brazilian statistics are equivalents as international leading:

- The statistics increases proportionally to the population.
- The Brazilian Unified Health System/SUS offers free public services treatments based on traditional oncololy:
 - Chemotherapy, Radiotherapy, Surgery and hormonal suppressors.
- **Immunotherapy** is not recognized as a treatment yet, in Brazil
- **mEHT** is not authorized as a Cancer treatment yet, in Brazil

The Brazilian Government did not consider yet the possibility to offer mEHT to population.

For a while, the patients from public health service in Brazil - will be treated by the “main stream”- they hve no other choice.





The Main Stream is a Great Business



Cultural concept

**“The possible treatment is QT – Main Stream”
The Medicine Federal Council do not consider the
effectiveness of mEHT.**

They believe in statistical significance



It has increased the
interested on the benefits
mEHT.

There is a pent up demand
on complementary
treatments for cancer.

Another stream is rising up in Brazil
... and in the world!



Profile of Brazilian patients on IMBiologica

- 82% between 40 e 70 years
- 68% female
- 87% polithreated patients
(Chemoterapy, Radiotherapy, Hormonal supression, Surgery, and Immunotherapy)
- 43% terminal patients
- 5% first cancer treatment: They refuses the traditional treatments.

AIM - Case Report

- Patients with **CA EsterioNeuroblastoma** treated with mEHT and supportive therapies.
- Patient historical evolution of malignancy during treatment with traditional oncology.
- Present images and results with mEHT treatment and other support therapies used.

It does not intended to offer scientific data, but rather a clinical report.

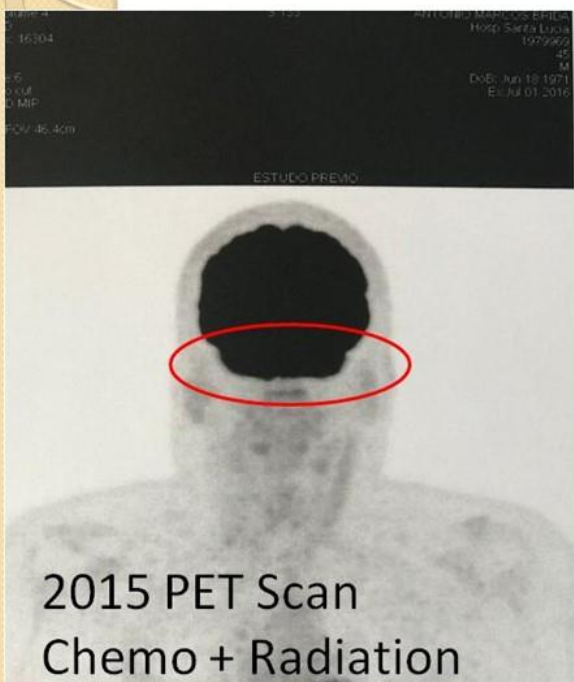
Patient Profile

M. Brida: Male, White skin, 47 years old

- 2014 diagnosed C30- CA EsterioNeuroblastoma
- 4 years treating by traditional methods.
- Poly-treated patient
 - CT, RT, and 3 sections of Immunotherapy
- Hopeless, he begins mEHT as a **last possibility**.

M. Brida:

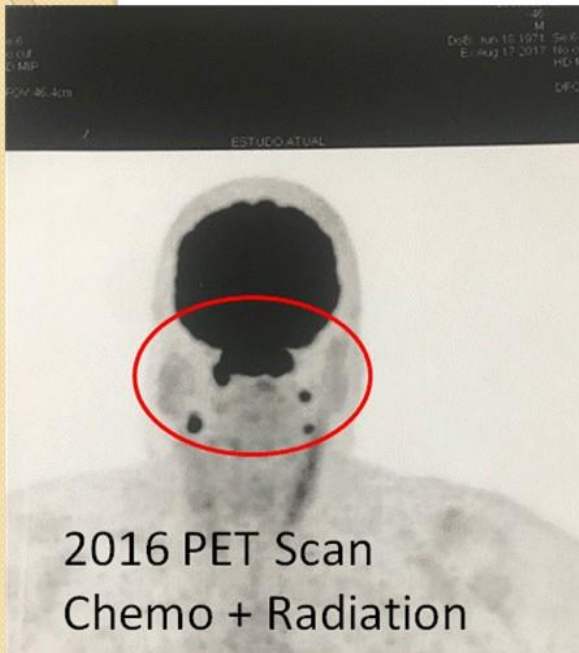
Male, White skin, 47 years old



2014 diagnosis

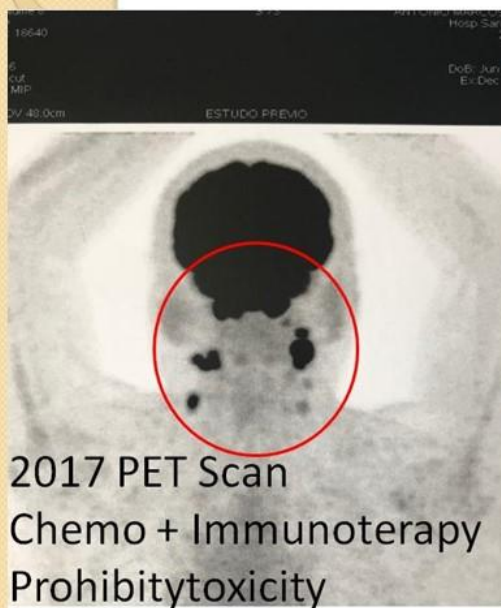
2015 - Patient was treated with Chemo and Radiotherapy.

M.Brida:
Male, White skin, 47 years old



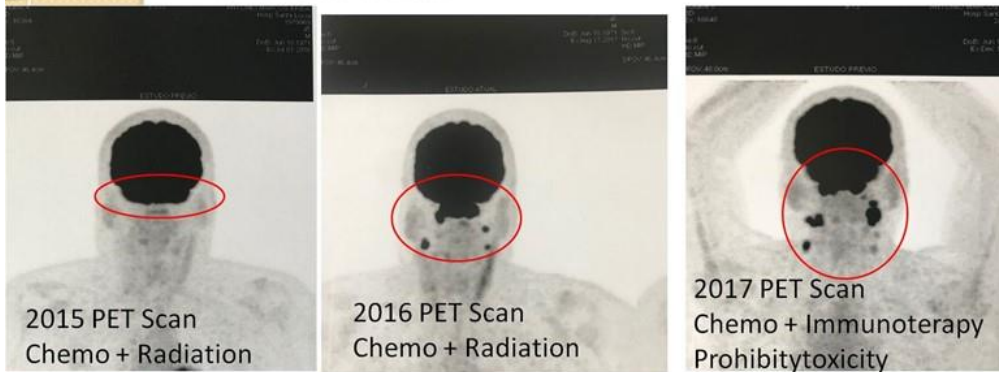
- 2016 - Identified the expansion of malignant cells to neck lymphonodes.
- In expansion

M. Brida:
Male, White skin, 47 years old



- 2017- Expansion of malignant,
- Treated with stronger QT which has caused rejection.
- The MD decided for Immunotherapy;
- Due hard toxicity, the MD decided to interrupt the treatment, after third section.

M Brida



- Swollen face on left side.
- Convergent view (Strabic), Double vision.
- Depleted immunity, Depressed, unmotivated, social isolation.
- Unable to work, suffering sequel from previous treatments.
- Weight loss of 20 kilos.
- Denial: Smoking, alcoholism.
- Confirms: insomnia, sedentary, unrestricted feeding.

2018 - Phase 3: mEHT + IMB integrative program from January to April 2018.

- Diet: Reduced intake of simple carbohydrates, Dra. Joana Budwig, Gerson therapy; Reduce inflammation, increase functionalities;
- Medium size bolus electrode applied on the face- left side.
- eMHT 3 X week 120W/ 60min. 12 sessions/monthly X 3 months
- Homeopatic support.
- Suggested "Health life stile" ;
- Oxygen therapy by Manfred Von Ardene (36 session - 20 min), Galvanic micro current (36 session - 20 min); Magneto therapy (36 session 20 min), Rife frequency (36 session 20 min)
- Ozonated blood therapy+ Endovenose supplementation (vitamins, minerals, amino acids) + VIT D3+ Curcumin + DCA + CBD.
- O3 Rectal 3 X week + other detox and eletrotheraopies;

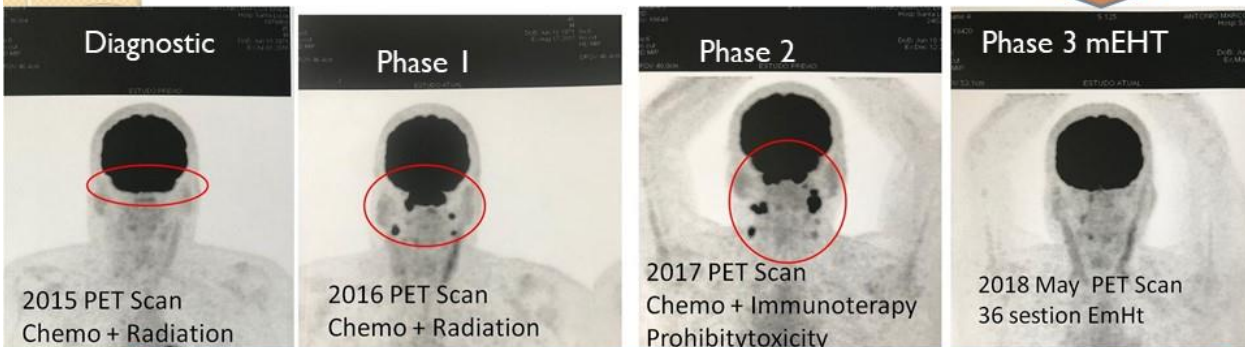
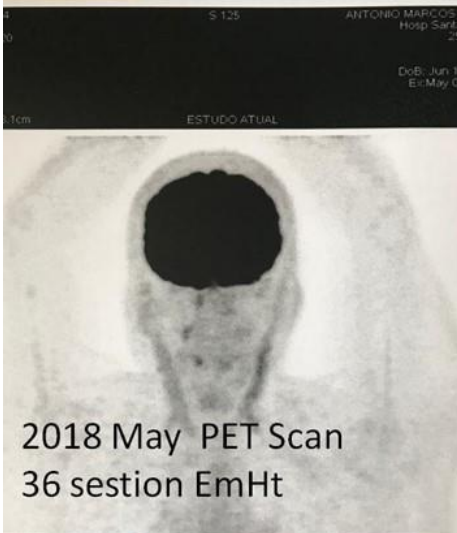
Phase 3: mEHT + IMB Integrative Program

After 36 session of mEHT, shows the clinical impression:

- 100% reduction of facial edema,
- 80% reduction of strabism.

PETscan Dez/17 X PETscan May /18

“Resolution of hypermetabolism on nasopharyngeal lesion in the inferior turbinate medial wall of the left maxillary sinus and bilateral cervical lymphonodes.”



- The patient continues with dietary habits and also with follow-up with traditional oncology.
- The ophthalmologist suggests a surgical intervention to adjust the remaining strabismus.
- Follow-up every six months with IMBiologica.
- Until now **he is doing good!**

Thanks Professors... You are building great knowledge!
We are facing the patient , trying to transform the
research results in

Reality..

Health ...

Happiness ...

for patients and his families!



Instituto de
**MEDICINA
BIOLÓGICA**